



# Cutaneous alternariosis in a liver transplant recipient

Raquel Vieira<sup>1</sup>, Júlio Veloso<sup>2</sup>, Ana Afonso<sup>3</sup> and Ana Rodrigues<sup>1</sup>

Departments of <sup>1</sup>Dermatology, <sup>2</sup>Hepatic Transplantation and <sup>3</sup>Pathology, Curry Cabral Hospital, Lisbon, Portugal

**Summary** We describe the case of a liver transplant patient with a cutaneous alternariosis due to *Alternaria infectoria*. Cutaneous lesions regressed with the decrease in daily doses of immunosuppressors. The skin lesion remains cicatricial after one year of follow-up.

**Key words** *Alternaria infectoria*, Alternariosis, Cutaneous lesions, Liver transplant

## Alternariosis cutánea en receptor de trasplante hepático

**Resumen** Se presenta un enfermo trasplantado de hígado, con alternariosis cutánea por *Alternaria infectoria*. Las lesiones cutáneas han regresado con la disminución de las dosis diarias de inmunosupresores y permanecen cicatriciales después de un año de seguimiento.

**Palabras clave** *Alternaria infectoria*, Alternariosis, Lesiones cutáneas, Trasplante hepático

Members of the genus *Alternaria* are ubiquitous, dematiaceous (pigmented) moulds, soil saprophytes. They are opportunistic fungi that mostly infect patients with immunosuppression or debilitating diseases [2,10]. These morbid processes may limit the host's ability to contain the infection. Nevertheless, lymphatic or haematogenous extensions are rare, the hosts defense mechanisms that contribute to localizing the lesions are unknown [7].

We describe the case of a liver transplant recipient with a cutaneous alternariosis due to *Alternaria infectoria* that regressed with a decrease in iatrogenic immunosuppression without concomitant antifungal therapy or surgery.

### Case report

A 67-year-old male farmer with hepatocarcinoma secondary to hepatitis B infection underwent liver transplant in May 2002. He was subsequently maintained with tacrolimus (5.5 mg/daily), mycophenolato mofetil (1000 mg/daily) and prednisone (10 mg/daily) immunosuppression.

In December he was admitted in the Dermatology Department due to three pruriginous erythematous nodules (0.5 to 1 cm), covered with a yellowish crust in both forearms and right knee (Figure 1), with one week of evolution. The patient did not remember a previous trauma.

Two skin biopsies were sent to histopathologic and mycological examination.

Histopathologic examination showed an intense inflammatory process in the dermis. Within the dermis there were round and oval spore-like structures that stained positively with periodic acid Schiff and Gomori-Grocott techniques (Figure 2).

Direct examination of bioptic specimen with 20% potassium hydroxide revealed hyaline septate hyphae. Cultures were performed on Sabouraud dextrose agar with and without chloranphenicol and cycloheximide, brainheart infusion agar, cornmeal, malt and blood agar at 24 and 37 °C. Fungal growth was obtained within 10 days in the majority of the inoculated plates. A cottony white and then grayish colony with a black reverse was obtained in Sabouraud's dextrose agar media. Microscopy revealed the colonies consisting of dark septate hyphae, dark, non-branched conidiophores and multiple darkly pigmented ovoidal conidia muriformes in groups and branched chains (Figure 3). Based on macro and microscopic characteristics the fungus was identified as *Alternaria infectoria*.

#### Dirección para correspondencia:

Dr. Raquel Vieira  
Alam Qta Sto António, 5, núcleo 3 – 2 Esq  
1600-675 Lisbon, Portugal  
Fax: +35 121 961 6427  
E-mail: raquelvieira@net.sapo.pt

Aceptado para publicación el 11 de noviembre de 2005

©2006 Revista Iberoamericana de Micología  
Apdo. 699, E-48080 Bilbao (Spain)  
1130-1406/01/10.00 :

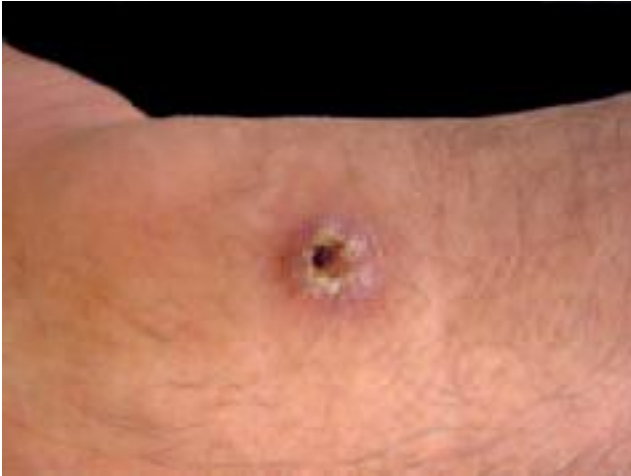

Figure 1. Erythematous nodule on the right forearm.

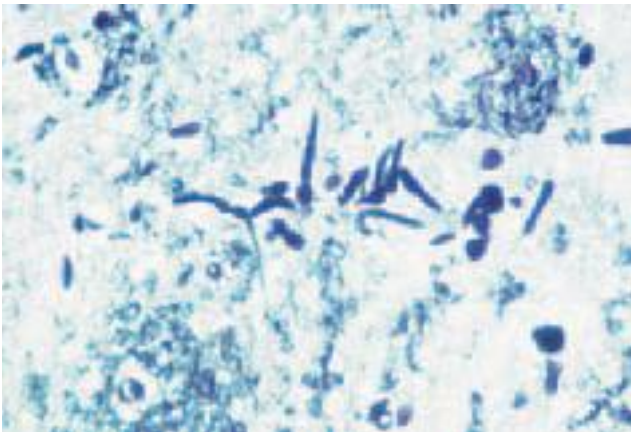


Figure 2. Round and oval spore-like bodies in the dermis (Grocott 40x).

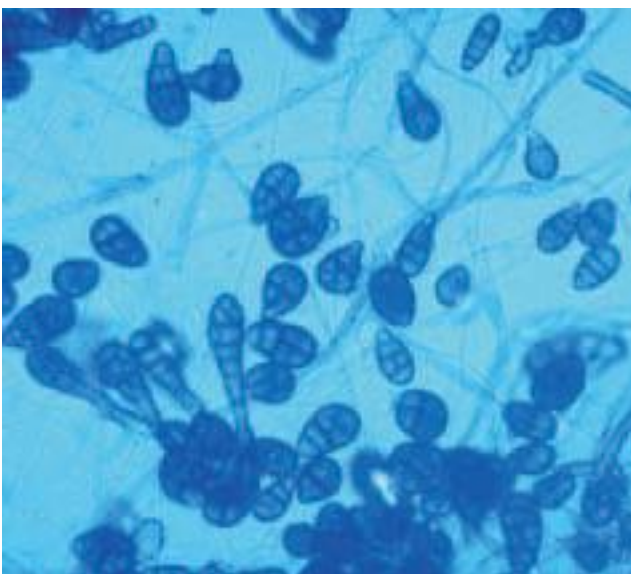


Figure 3. Microscopic morphology of *A. infectoria* (600x).

Identification to the species level was performed at Centraalbureau voor Schimmelcultures, The Netherlands.

In January 2003, daily doses of immunosuppressive drugs were reduced to: 2 mg/day of tacrolimus and 500 mg/day of mycophenolato mofetil. Therapy with prednisone was suspended. Within three months the cutaneous lesions regressed. Histopathologic examination of a skin biopsy revealed no fungal structures and mycologic direct and culture exams were negative.

In August 2003, it was diagnosed a recidive of the hepatocarcinoma, with metastasis in the dorsal paravertebral region, that was treated with radiotherapy. Skin lesions remain cicatricial after one year of follow-up.

## Discussion

Cutaneous alternariosis can no longer be considered a rare fungal infection. A recent review of the literature yielded 89 cases that met both histological and culture criteria of alternariosis [8]. In spite of the apparent awareness of this infection, namely in solid organ transplant recipients in whom these infections have been increasingly reported, some characteristics must be emphasized.

On the basis on anatomical characteristics there are several types of clinical symptoms. Cutaneous lesions are frequent and of two types epidermal and dermal [3]. Scaly erythema and ulcerative lesions in the epidermal form and plaques, papules, pustules, and crusts are present in the dermal type [4]. It is usually believed that this type of lesions are the result of traumatic implantation of the agents. Most reports are of dermal cutaneous alternariosis and the arms and legs are the most common sites of infection. Dermatologic differential diagnosis includes several types and low specificity of the lesions such as neoplastic diseases (Kaposi sarcoma), other fungal infections (sporotrichosis) as well as other parasitic cutaneous infections (leishmaniasis) [12].

*Alternaria* spp are prevalent in the environment, being usually isolated as laboratory contaminants, frequently cultured from the skin surface and it is considered a saprophyte [11]. Their pathologic significance must be evaluated. The isolation in culture must be complemented by histologic evidence of its presence in tissues [5].

*Alternaria tenuissima*, *Alternaria alternata* and *Alternaria chartarum* are the species most frequently involved in human pathology [1]. In our case an *A. infectoria* was isolated, one of the less frequently described in literature as human pathogen.

The treatment must include, if possible, the correction of the predisposition factors [4], whenever possible. The literature reports that the management of the infection was clearly facilitated, as was the case in our patient, when the predisposition factors were corrected and antifungal therapy was applied. However, the case in this report was unusual because the cure of the infection was achieved reducing the immunosuppressor therapy, without the use of antifungals or surgery [4]. The treatment of *Alternaria* spp infections is not standardized [7,8] so the clinician must, after a correct dermatologic and mycologic diagnosis, decide what are the best options in each particular case.

## References

1. Acland KM, Hay RJ, Groves R. Cutaneous infection with *Alternaria alternata* complicating immunosuppression: successful treatment with itraconazole. *Br J Dermatol* 1998; 138: 354-356.
2. Badillet G, Bièvre C, Guého E. Champignons contaminants des cultures. In: Badillet G (Ed.) *Champignons opportunistes*. Tome II. *Champignons filamenteux*. Paris, Ed Varia, 1987: 167-174.
3. Badillet G. Les alternariosis cutanées. *Revue de la littérature*. *J Med Mycol* 1991; 118: 59-71.
4. Iwatsu T. Cutaneous alternarioses. *Arch Dermatol* 1988; 124: 1822-1825.
5. Kim JO, Kim GH, Kim BC, Lee KS. Cutaneous alternariosis in a renal transplant recipient. *Int J Dermatol* 2003; 42, 630-631.
6. Kwong-Chung KJ, Bennett JE. Subcutaneous Phaeohyphomycosis. In: Kwong-Chung KJ (Ed.) *Medical Mycology*. Philadelphia, Lea & Febiger, 1992: 631-634.
7. Like KE, Miller NS, Towne L, Merz WG. A case of cutaneous ulcerative alternariosis: rare association with diabetes mellitus and unusual failure of itraconazole treatment. *Clin Infect Dis* 2001; 32: 1178-1187.
8. Magina S, Lisboa C, Santos P, Oliveira G, Lopes J, Rocha M, Mesquita Guimarães J. Cutaneous alternariosis by *Alternaria chartarum* in a renal transplanted patient. *Br J Dermatology* 2000; 142: 1261-1262.
9. Mitchell AJ, Solomon AR, Beneke ES, Anderson TF. Subcutaneous alternariosis. *J Am Acad Dermatol* 1983; 8: 673-676.
10. Percebois G, Biava MS, Kures L. Discussion du pouvoir pathogène de certaines espèces d'*Alternaria*: à propos de trois observations. *Bull Soc Fr Myc Med* 1978; 7: 15-18.
11. Richardson MD, Warnock DW. Phaeohyphomycosis. In: Richardson MD, Warnock DW (Eds.) *Fungal infection diagnosis and treatment*. London, Blackwell Science, 1997: 227-231.