



## Note

# Phenotypic and molecular identification of *Coccidioides posadasii* in a patient evaluated for bilateral lung transplantation

Analía Fernández<sup>a,c</sup>, Fernanda Landaburu<sup>c</sup>, Gabriela Lopez-Daneri<sup>c</sup>, Claudia Nagel<sup>b</sup>, Patricia Di Giorgio<sup>b</sup>, Cristina Iovannitti<sup>c</sup>, Marta Tokumoto<sup>a</sup>, María Teresa Mujica<sup>c,\*</sup>

<sup>a</sup> Hospital Universitario Fundación Favaloro, Laboratorio Central Servicio de Microbiología, Argentina

<sup>b</sup> Hospital Universitario Fundación Favaloro, División Infectología, Argentina

<sup>c</sup> Departamento de Microbiología, Parasitología e Inmunología, Facultad de Medicina de la Universidad de Buenos Aires, Buenos Aires, Argentina

## ARTICLE INFO

### Article history:

Received 23 September 2011

Accepted 31 January 2012

Available online 22 February 2012

### Keywords:

Coccidioidomycosis

*Coccidioides posadasii*

Organ transplant

Transplant

Molecular identification

## ABSTRACT

**Background:** Coccidioidomycosis is an endemic fungal infection caused by *Coccidioides immitis* and *Coccidioides posadasii*. It can be particularly severe in transplant recipients that have a current or a previous coccidioidal infection. Fatal case of coccidioidomycosis has been described in this group of patients.

**Aims:** We report a severe case of pneumonia caused by *C. posadasii* in a 29 year-old white woman that had been admitted to hospital as part of the evaluation for bilateral lung transplantation. The patient was a native and resident of Catamarca, Argentina. Molecular methodologies contributed to the species identification.

**Methods:** Clinical, laboratory records and microbiological tests were carried out to diagnose the infection and to identify *C. posadasii*.

**Results:** A fungus was isolated from BAL culture. Phenotypic characterization, specific PCR and experimental animal inoculation demonstrated the presence of *C. posadasii*. The patient responded well to amphotericin B deoxycholate. Lung transplantation was postponed.

**Conclusions:** Specific PCR can be an important alternative for the correct identification of *C. immitis* or *C. posadasii* in laboratories with implemented molecular biology tools. This case emphasizes the need for a systematic assessment in organ transplant units of patients inhabiting endemic areas of coccidioidomycosis.

© 2011 Revista Iberoamericana de Micología. Published by Elsevier España, S.L. All rights reserved.

## Identificación fenotípica y molecular de *Coccidioides posadasii* en una paciente examinada para un trasplante bipulmonar

## RESUMEN

**Antecedentes:** La coccidioidomycosis es una infección micótica endémica debida a *Coccidioides immitis* y *Coccidioides posadasii*. Su presencia en receptores de un trasplante puede revestir especial gravedad, en particular en pacientes con una infección activa o previa por *Coccidioides*. En este grupo de pacientes se han descrito casos letales de la infección.

**Objetivos:** Describimos un caso grave de neumonía debida a *C. posadasii* en una mujer blanca de 29 años de edad, que fue ingresada en el hospital como parte de la valoración de un trasplante bipulmonar. La paciente había nacido y residía en Catamarca, Argentina. La metodología molecular contribuyó a la identificación de la especie.

**Métodos:** Para establecer el diagnóstico de la infección e identificar *C. posadasii*, se efectuaron una exploración clínica, pruebas de laboratorio y exámenes microbiológicos.

**Resultados:** A partir del cultivo del líquido de lavado broncoalveolar se aisló el hongo. La caracterización fenotípica, la reacción en cadena de la polimerasa específica y la inoculación experimental a un animal demostraron la presencia de *C. posadasii*. La paciente respondió al tratamiento con anfotericina B desoxicolato. El trasplante de pulmón se difirió.

### Palabras clave:

Coccidioidomycosis

*Coccidioides posadasii*

Trasplante de órganos

Trasplante

Identificación molecular

\* Corresponding author.

E-mail address: [mtmujica@gmail.com](mailto:mtmujica@gmail.com) (M.T. Mujica).

**Conclusiones:** La RCP específica puede ser una importante alternativa para la correcta identificación de *C. immitis* o *C. posadasii* en los laboratorios con medios implementados de biología molecular. El caso descrito destaca la necesidad de que, en las unidades de trasplante de órganos, se efectúe una valoración sistemática de los pacientes que viven en áreas endémicas de coccidioidomycosis.

© 2011 Revista Iberoamericana de Micología. Publicado por Elsevier España, S.L. Todos los derechos reservados.

Coccidioidomycosis is a fungal infection caused by *Coccidioides immitis* and *Coccidioides posadasii*.<sup>6</sup> It is commonly found in the Americas, particularly in southwestern United States and bordering regions of northern Mexico. Lower endemicity has been described in Central and South America.<sup>2,3,10,11,13</sup>

The clinical features of the infection include self-limited, primary respiratory disease, chronic pulmonary disease, and extrapulmonary dissemination. It could be severe in immunocompromised patients.<sup>5</sup>

We report a severe case of pneumonia caused by *C. posadasii* in a patient evaluated for bilateral lung transplantation. Different laboratory approaches were implemented for the correct diagnosis of coccidioidomycosis. Furthermore, a molecular method was the key for the proper identification of the etiologic agent.

### Case report

A 29-year-old white woman was admitted to Favaloro University Hospital, Buenos Aires, for routine evaluation prior to bilateral lung transplantation. The patient was a native resident of Catamarca, in the west part of Argentina. She had a history of smoking for eight years (17–25 years old).

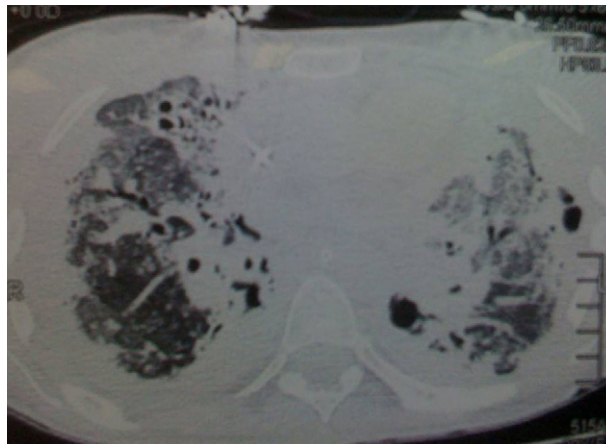
Six years earlier, she was diagnosed with a malignant non-Hodgkin lymphoma. She was treated with chemotherapy, radiotherapy and autologous hematopoietic stem cell transplantation. After radiation treatment, she developed pneumonitis, bilateral pneumothorax, and lung fibrosis. She received home oxygen treatment, prednisone (8 mg/day) and azathioprine (2 mg/kg/day).

On admission, she showed progressive dyspnoea and fever for one week. White blood cell counts showed  $33 \times 10^9/L$ . X-ray of the chest revealed bilateral pulmonary infiltrates, mild left pleural effusion and loss of lung volume. She was treated with bronchodilators, required mechanical ventilation and inotropic therapy. Fiberoptic bronchoscopy was performed before initiating an empirical antibiotic treatment with cefepime (1 g/12 h), and clarithromycin (500 mg/12 h) for 14 days. Computerized axial tomography (CT) scans revealed diffuse interstitial lung disease and interlobular septal thickening. Bronchiectasis and cystic lesion in the pulmonary apex were observed (Fig. 1).

Mycological evaluation of bronchoalveolar lavage (BAL) was conducted. Microscopic examination of clinical specimen did not show the presence of pathogenic microorganisms. However, 20 days later, mycelial growth was detected in Sabouraud glucose agar (SGA) with chloramphenicol. Macromorphological and microscopic examination of fungal growth suggested *Coccidioides* spp. isolate. The patient started therapy with intravenous voriconazole 300 mg/12 h for 15 days. When the diagnosis of coccidioidomycosis was established, amphotericin B deoxycholate (0.7 mg/kg/day) was prescribed. As favorable resolution was observed, the inotropic therapy was suppressed.

She was referred to another institution for medical and nursing care. She received a total of 1105 g of amphotericin B and lung transplant was momentarily postponed.

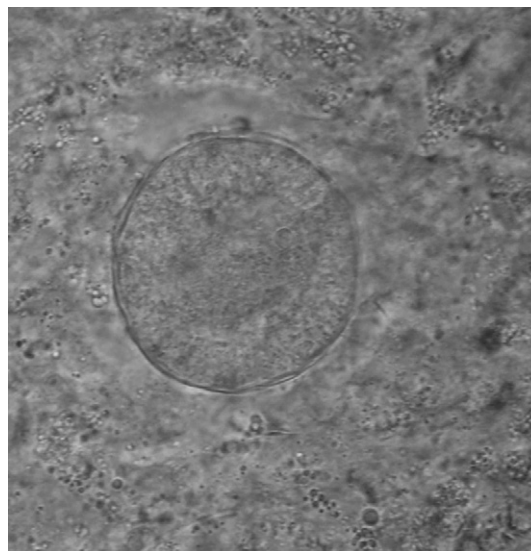
Hamster (*Mesocricetus auratus*) intratesticular inoculation and molecular identification were performed with the culture isolated from the BAL specimen. Two hamsters were inoculated intratesticularly with 0.1 mL of arthroconidia concentrated suspension and



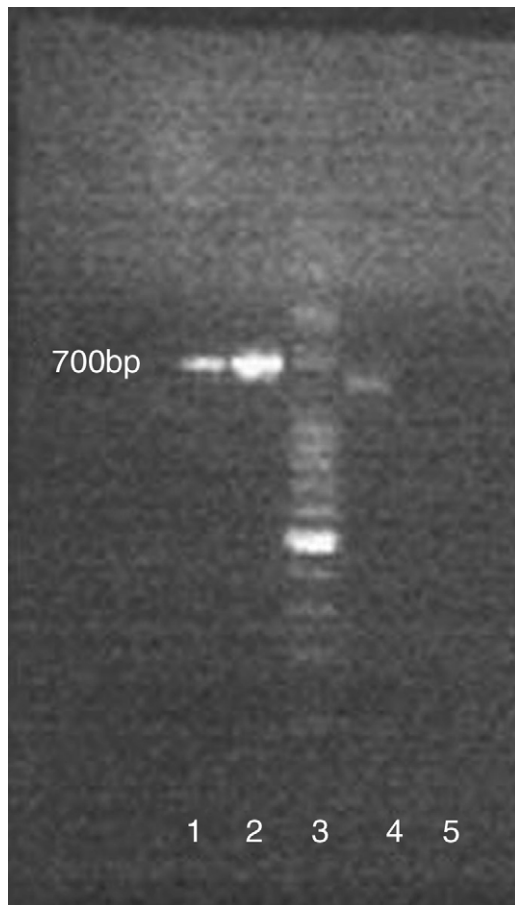
**Figure 1.** Lung computerized tomography scans showing bilateral bronchiectasis, thickening of interlobular septa, mild left pleural effusion and loss of lung volume.

animals were maintained as suggested.<sup>9</sup> After seven days, orchitis was developed and endosporulating spherules were observed in the purulent material (Fig. 2).

Molecular identification was undertaken using a PCR (Polymerase Chain Reaction) assay described.<sup>12</sup> Two *Coccidioides* strains were studied: one was isolated and recovered from the patient's BAL specimen, and the other was a *C. immitis* strain obtained from Roche Molecular Systems Culture Collection (RMSCC) 5273.<sup>6</sup> The two strains were cultured at 37 °C for one week on YPD broth (yeast extract 1%, peptone 2%, and dextrose 2%). Fungal mass was fixed by a final concentration of approximately



**Figure 2.** Spherule of *Coccidioides* spp. observed in the purulent material obtained from the orchitis developed in the hamster. Note the thick wall of the spherule containing endospores in formation attached to the wall.



**Figure 3.** PCR amplification of coccidioidal DNAs. Lanes 1, 2: amplification of *Coccidioides immitis* RMSCC 5273. Lane 3: A 50-bp DNA ladder was used to estimate product sizes (numbers on the left side of the gel are in base pairs). Lane 4: amplification of *Coccidioides* spp. isolate from BAL culture. Lane 5: negative control.

70% ethanol for 48 h and its survival was checked. Genomic DNA was extracted.<sup>14</sup> DNA was quantified and its purity was evaluated to 260 nm (SmartSpec™ 3000 Spectrophotometer; Bio-Rad, Hercules, CA). Specific primers for *C. immitis* and *C. posadasii* were used.<sup>12</sup> The nucleotide sequences of the primers were *Coi9-1F* (5'-TACGGTGAATCCCGATACA-3') and *Coi9-1R* (5'-GGTCTGAATGATCGACGCA-3'). The selected primer set amplifies a 720 bp amplicon that corresponds to nucleotide position 660,313–661,032 of *C. immitis* contig 2.2 (GenBank's accession number AAEC02000002) and position 676,142–676,861 of *C. immitis* supercont 2.1 (GenBank's accession number NW\_001509361.1). Two different mobilities presented the DNA fragment of *Coccidioides* spp. The DNA fragment amplified from the BAL culture was, as expected, shorter than that from *C. immitis*, and the species was identified as *C. posadasii* (Fig. 3).

An immunodiffusion assay (ID) was conducted using a patient's serum sample and *C. posadasii* antigen prepared in our laboratory. Briefly, *C. posadasii* antigen was prepared from cultures in the mycelial phase in 2% glucose and 1% yeast extract broth for approximately 30 days at 37 °C on gyratory shaker at 90 rpm. Each culture was killed with a concentration 1:5000 thimerosal (ethyl(2-mercaptobenzoato-(2-)-O,S)mercurate(1-)-sodium) for 24 h. The supernatant was collected and concentrated 10 times by evaporation. The antigen was standardized and stored at 4 °C. After the evaluation of the patient serum in ID a positive reaction was obtained, further confirming the diagnosis of coccidioidomycosis.

## Discussion

Coccidioidomycosis is currently considered a reemerging disease.<sup>3,5</sup> In the case discussed here the patient suffered from an extensive pulmonary involvement caused by *C. posadasii*, which exacerbate her pulmonary symptoms.

Endospores-containing spherules or small spherical structures were not observed in the BAL sample, probably due to the low sensitivity of this procedure.<sup>11</sup> Based on the epidemiological features of the case, a putative diagnosis of *Coccidioides* spp. was made,<sup>3,10</sup> which was latter supported by the characteristics of the obtained culture from BAL clinical samples. Because *Coccidioides* spp. culture morphologically resembles species of *Malbranchea*, further tests to confirm the presence of *Coccidioides* spp. are necessary. The in vivo conversion of mycelial form to spherules by animal inoculation is also a useful method to confirm the presence of *Coccidioides* spp. in clinical specimens.<sup>4,10</sup>

Since *C. immitis* and *C. posadasii* species seem to have almost identical clinical presentations and antifungal susceptibility profiles,<sup>11</sup> at first glance their differentiation in the clinical laboratory seem unnecessary. However, from the epidemiological point of view, it is very important to know the distribution of the different strains causing coccidioidomycosis in the Americas. Specific PCR is a good alternative for the correct identification of *C. immitis* or *C. posadasii* in laboratories with implemented molecular biology tools as it was very helpful confirming the diagnosis of this difficult case.

Timing and magnitude of antibody response are directly related to the integrity of the patient's immune system and specific clinical presentation of infection.<sup>11</sup> Immunodiffusion assay was useful in the diagnosis of this case of coccidioidomycosis.

Coccidioidomycosis can be particularly severe in transplant recipients,<sup>1,7,8</sup> and risk factors after organ transplant include previous or present coccidioidal infection. Lung transplantation was postponed because suppression of allograft rejection involves impairing the cellular immune response required to control coccidioidal infection.

Different laboratory approaches were used to achieve the diagnosis of coccidioidomycosis. The systematic evaluation of the clinical sample to correctly diagnose cases of coccidioidomycosis is crucial, especially in patients inhabiting or visiting endemic areas before initiating any immunosuppressive therapy.

## Acknowledgements

This research was supported by Grant UBACyT 20020100100 554, Universidad de Buenos Aires.

## References

- Blair JE, Logan JL. Coccidioidomycosis in solid organ transplantation. *Clin Infect Dis*. 2001;33:1536–44.
- Bonardello NM, de Gagliardi CG. Intradermal reactions with coccidioidins in different towns of San Luis Province. *Sabouraudia*. 1979;17:371–6.
- Canteros CE, Toranzo A, Ibarra-Camou B, David V, Carrizo SG, Santillán-Iturres A, et al. La coccidioidomycosis en Argentina, 1892–2009. *Rev Arg Microbiol*. 2010;42:261–8.
- Clemons KV, Capilla J, Stevens DA. Experimental animal models of coccidioidomycosis. *Ann N Y Acad Sci*. 2007;1111:208–24.
- Cox RA, Magee DM. Coccidioidomycosis: host response and vaccine development. *Clin Microbiol Rev*. 2004;17:804–39.
- Fisher MC, Koenig GL, White TJ, Taylor JW. Molecular and phenotypic description of *Coccidioides posadasii* sp. nov., previously recognized as the non-California population of *Coccidioides immitis*. *Mycologia*. 2002;94:73–84.
- Halloran PF. Immunosuppressive drugs for kidney transplantation. *N Engl J Med*. 2004;351:2715–29.
- Miller MB, Hendren R, Gilligan PH. Posttransplantation disseminated coccidioidomycosis acquired from donor lungs. *J Clin Microbiol*. 2004;42:2347–9.
- National Research Council. *Guide for the care and use of laboratory animals*. Washington, DC: National Academy Press; 1996.

10. Negroni R. Evolución de los conocimientos sobre aspectos clínico-epidemiológicos de la coccidioidomicosis en las Américas. *Rev Arg Microbiol.* 2008;40:246-56.
11. Saubolle MA, McKellar PP, Sussland D. Epidemiologic, clinical, and diagnostic aspects of coccidioidomycosis. *J Clin Microbiol.* 2007;45:26-30.
12. Umeyama T, Sano A, Kamei K, Niimi M, Nishimura K, Uehara Y. Novel approach to designing primers for identification and distinction of the human pathogenic fungi *Coccidioides immitis* and *Coccidioides posadasii* by PCR amplification. *J Clin Microbiol.* 2006;44:1859-62.
13. Wanke B, Lazera M, Monteiro PC, Lima FC, Leal MJ, Ferreira Filho PL, et al. Investigation of an outbreak of endemic coccidioidomycosis in Brazil's north-eastern state of Piauí with a review of the occurrence and distribution of *Coccidioides immitis* in three other Brazilian states. *Mycopathologia.* 1999;148:57-67.
14. Yamakami Y, Hashimoto A, Tokimatsu I, Nasu M. PCR detection of DNA specific for *Aspergillus* species in serum of patients with invasive Aspergillosis. *J Clin Microbiol.* 1996;34:2464-8.