



# Isolation of *Paracoccidioides brasiliensis* from the nine-banded armadillo *Dasypus novemcinctus*, in an endemic area for paracoccidioidomycosis in Colombia

Germán G. Corredor<sup>1</sup>, John H. Castaño<sup>1</sup>, Luis A. Peralta<sup>1</sup>, Soraya Díez<sup>2</sup>, Myrtha Arango<sup>2</sup>, Juan McEwen<sup>2</sup> and Angela Restrepo<sup>2</sup>

<sup>1</sup>Facultad de Medicina Veterinaria y Zootecnia, Universidad de Caldas, Manizales; <sup>2</sup>Unidad de Biología Molecular y Grupo de Micología, Corporación para Investigaciones Biológicas (CIB), Medellín, Colombia.

## Summary

The microniche of the dimorphic fungus *Paracoccidioides brasiliensis* remains undefined in spite of the many attempts to isolate it from natural sources. Until recently, knowledge was also scanty concerning the presence of natural infections in animals; however, in the last decade, the fungus has been repeatedly isolated from the nine-banded armadillo, *Dasypus novemcinctus* in Brazil. A study aimed at determining the presence of infected armadillos in one of the paracoccidioidomycosis endemic areas of Colombia (Manizales, Department of Caldas) was undertaken. Based on the records of paracoccidioidomycosis patients available in the regional hospital, we selected a locality corresponding to a permanent resident, and found that it also had armadillo's burrows. Counting with the proper authorization, two animals were captured, sacrificed under prolonged anaesthesia and various internal organs cultured in mycological media. PCR with specific *P. brasiliensis* primers was also done. The fungus was isolated from the mesenteric lymph node of one of the animals; fungal DNA amplification was positive in the same specimen as well as in the liver. The isolate from the Colombian armadillo indicates that these animals are regular hosts to *P. brasiliensis* in at least two endemic countries. Due to the restricted life pattern of these mammals they represent an important link with the natural habitat of the fungus. Consequently, a study of their movements and habits could prove rewarding in the search for this habitat.

## Key words

*Paracoccidioides brasiliensis* habitat, Armadillo, Endemic area, Paracoccidioidomycosis

## Aislamiento de *Paracoccidioides brasiliensis* a partir de un armadillo de nueve bandas (*Dasypus novemcinctus*), en área endémica para la paracoccidioidomycosis en Colombia

## Resumen

El micronicho del hongo dimórfico *Paracoccidioides brasiliensis* permanece aun desconocido, a pesar de múltiples búsquedas. Hasta hace poco, también eran escasos los informes sobre infección natural en animales; no obstante, en el Brasil, en la última década, este microorganismo ha sido aislado repetidamente del armadillo de nueve bandas, *Dasypus novemcinctus*. El propósito del presente estudio fue buscar en una zona endémica para la paracoccidioidomycosis en Colombia (Manizales, Departamento de Caldas), la posible presencia de armadillos infectados por el hongo. Con base en las historias de pacientes con paracoccidioidomycosis disponibles en el hospital regional de la zona, se escogió una finca donde uno de ellos había vivido y trabajado toda su vida; este sitio tenía,

### Dirección para correspondencia:

Dra. Angela Restrepo  
Corporación para Investigaciones Biológicas (CIB),  
Carrera 72A- # 78B-141,  
Medellín, Colombia  
Tel.: +574 441 0855; Fax: +574 441 5514  
E-mail: angelares@epm.net.co

Aceptado para publicación el 30 de septiembre de 1999

además, madrigueras de armadillo. Con autorización de las autoridades respectivas, se capturaron en tal sitio dos armadillos, que fueron sacrificados por anestesia prolongada, cultivándose varios de sus órganos en medios para hongos. Se utilizó también la prueba de PCR, empleando dos iniciadores específicos para *P. brasiliensis*. El hongo fue aislado del ganglio mesentérico del primer armadillo; igualmente, la amplificación del ADN fue positiva en este mismo animal, tanto en el ganglio como en el hígado. La presencia de *P. brasiliensis* en un armadillo colombiano indica que estos mamíferos son sus hospederos habituales, al menos, en dos países del área endémica. Debido a sus costumbres regulares, los armadillos constituyen una conexión importante con el hábitat del hongo. Por consiguiente, un estudio encaminado a determinar sus hábitos, pudiera ser de importancia en la determinación del hábitat de *P. brasiliensis*.

*Palabras clave*

Hábitat de *Paracoccidioides brasiliensis*, Armadillo, Área endémica, Paracoccidioidomicosis

Our knowledge concerning the natural habitat of the dimorphic fungus *Paracoccidioides brasiliensis*, the etiologic agent of paracoccidioidomycosis (PCM), is only partial [1,2]. The number of *P. brasiliensis* isolates from natural substrates is small; taking the soil as an example, the fungus has been isolated once from Argentina [3], twice from the same farm in Venezuela [4] and once from a coffee growing area in Brazil [5]. The fungus has also been recovered from a dog chow possibly contaminated with soil [6]. Reports on the isolation of the fungus from naturally infected animals are also rare and include bat guano [7] and penguin feces [8], as well as histopathologic observation in a squirrel monkey [9]. Since 1986, however, more consistent information has been gathered concerning *P. brasiliensis* infections in the nine-banded armadillo *Dasypus novemcinctus* [10].

Quite fortuitously, while searching for *Leishmania* in sylvan reservoirs in the Pará State of the Brazilian Amazon, Naiff *et al.* found that several nine-banded armadillos harbored *P. brasiliensis* in their spleens and/or livers [11]. Shortly thereafter, the same authors repeated the observation in armadillos captured in a different region of the same State [12]. More recently, Silva *et al.* [13], Bagagli *et al.* [10], and Macedo *et al.* [14], confirmed the presence of natural *P. brasiliensis* infections in armadillos from different paracoccidioidomycosis endemic areas of Brazil. Nonetheless, the presence of natural infections in this mammal has not been informed from other Latin American countries.

We report here the isolation of *P. brasiliensis* from one of two nine-banded armadillos captured in an endemic area for paracoccidioidomycosis in Colombia. The isolation was made from a mesenteric lymph node and, additionally, specific fungal DNA amplification by PCR proved positive in this specimen as well as in the liver.

**MATERIALS AND METHODS**

*Area of study.* The records of 20 patients with paracoccidioidomycosis that had been detected through the National Mycology Diagnostic Net Services of the Instituto Nacional de Salud, Santa Fé de Bogotá, during the period 1987-1997, at the Hospital Santa Sofía in Manizales, Department of Caldas, Colombia, were analyzed [15,16]. Particular attention was given to those cases that have lived and worked within the same locality, in the rural areas surrounding the city of Manizales. Interviews were arranged with patients and/or their relatives. A farm where one of the patients had always lived and worked was chosen for study (Figure 1). It was located at 05°05'08. 3" latitude north and 075°36'18. 6" length

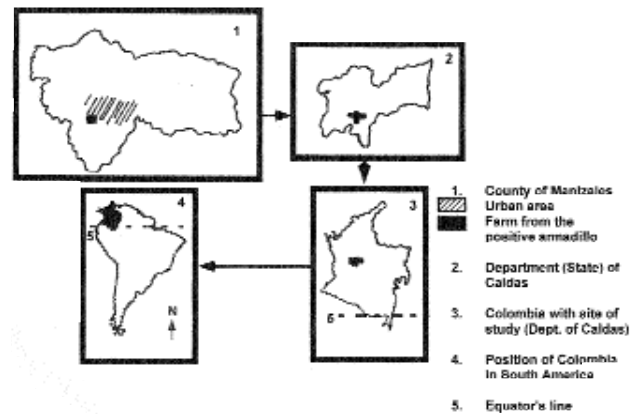


Figure 1. Location of the study area in the Department (State) of Caldas, in Colombia.

west, 1,300 meters above sea level. The temperature fluctuates between 18-24°C and the annual precipitation ranges from 1,700 to 2,500 mm. The farm's soil has an acid pH, is moderately fertile, rich in organic matter, loose and porous; the latter circumstance allows an adequate gaseous exchange; also, this type of soil has the capacity to retain a high humidity [17]. The terrain is planted with coffee but banana plants and some other native trees, such as *Cecropia telenivea* (yarumo), *Guadua angustifolia* (guadua), *Albizia carbonara* (carbonero), are also present. These ecologic conditions allow to place the farm in the very humid pre-mountainous forest (Holdridge system) [18]. In Colombia, this forest corresponds to that of the coffee growing terrains [17,19] and simultaneously, to the habitat of the nine-banded armadillo [20].

*Capture of armadillos.* Permission was obtained from the wild-life preservation authorities (Instituto Colombiano Agropecuario-ICA, Corpocaldas branch of ICA), and with the aid of a specialized hunter, two male adult *D. novemcinctus* were captured within a period of three months, in the selected locality. Immediately after capture, the animals were injected intramuscularly with a neuroleptoanesthetic combination (100 mg ketamine, 20 mg xylazine in 1 ml distilled water) and sacrificed by prolonged anesthesia. After thorough cleansing, autopsy was performed and samples from the liver, the spleen, the lungs and the mesenteric lymph nodes were taken for culture and animal inoculation. They were suspended in phosphate buffered saline and sent under refrigeration to the reference laboratory (Corporación para Investigaciones Biológicas, Medellín) for further processing.

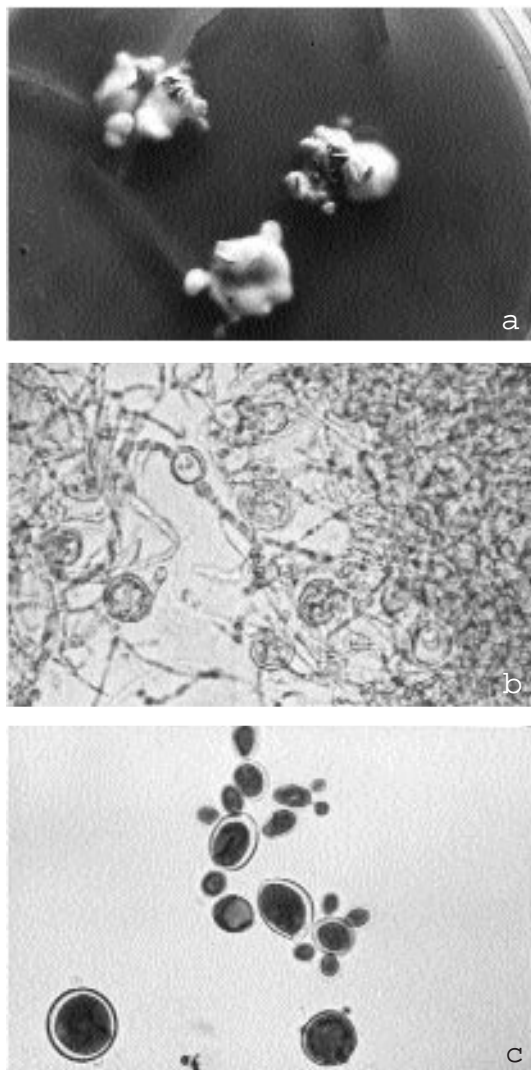


Figure 2. Primary isolation of *Paracoccidioides brasiliensis* from a mesenteric lymph node of a nine-banded armadillo. a) Mycelial growth at 24°C on Mycosel Agar, 6 weeks of incubation. Note multiple colonies, b) Microscopic appearance of the mycelial form. Observe septated hyphae and chlamydospore formation (cotton-blue preparation) (40x), c) Microscopic appearance of a yeast culture at 36°C in trypticase soy agar. Observe multiple budding yeast cells characteristic of *Paracoccidioides brasiliensis* (cotton-blue preparation) (40x).

**Processing of the specimens for culture and inoculation:** Upon receipt, the biopsies were minced and/or homogenized in tissue grinders. Both types of specimens were then plated by duplicate in Mycosel and Sabouraud glucose agars (BBL, Beckton Dickinson Microbiology Systems, USA), as well as in duplicate tubes with the modified MacVeigh and Morton liquid medium [21]. Cultures were incubated at 21-24°C in the dark, for eight weeks, with weekly readings. When growth occurred, microscopic observations were carried out and mycelial growth subcultured to Sabouraud glucose agar (BBL) with thiamine and asparagine, both at 0.1%, with incubation at 36°C in order to facilitate conversion to the yeast phase [1]. The latter type of growth was subjected to microscopic observation and the presence of multiple budding yeast cells was ascertained.

A portion of the homogenized tissues were used for inoculation into the peritoneal cavity of adult, male BALB/c mice, four per tissue. These animals were fed

with animal chow and acidified water, *ad libitum*. Ten weeks after inoculation they were sacrificed by prolonged ether anesthesia and their internal organs, cultured as described above. The remaining tissues were subjected to molecular biology procedures.

**PCR determination.** Homogenized tissues (lymph node, liver, spleen) from both the armadillos and the mice inoculated with their organs, were subjected to PCR [22,23]. DNA extraction was done following the first of the five techniques reported by Van Burik [24] with a modification, namely, the initial extraction step was done by grinding with mortar and pestle on the sample frozen by liquid nitrogen. The DNA pellet was suspended in 10 µl of TE buffer (10 mM tris, pH 9, 0.1 mM EDTA) and its purity was determined by agarose gel electrophoresis, using known DNA markers as standards.

PCR was performed with a PTC 100 thermal (MJ Research, USA) in a 0.2 ml thin wall PCR tubes (Axygen Scientific, USA). The PCR mixture (50 µl each) contained 10 ng of DNA, 25 pM of each primer, 1 X PCR buffer (10 mM tris-HCl [pH 8.8], 1.5 mM MgCl<sub>2</sub>, 50 mM KCl, 0.1% triton X-100), 0.2 mM (each) of the four deoxynucleoside triphosphates, and 1 U of *Taq* polymerase (Promega, USA).

Thermal cycling conditions for the universal primers ITS1, ITS4 [22] were as follows: Initial denaturation (95°C, 5 min), 30 cycles of denaturation (95°C, 50 s), annealing (50°C, 50s), primer extension (72°C, 50s) followed by one final cycle of primer extension (72°C, 7 min). When the specific primers gp43-1 (5' ATGATTTAGTTCTCTTAACCTGGCTCTT) and gp43-2 (5' CCTGCATCCACCATACTTCCTAGCCCA) [25] were used, the conditions were as follows: initial denaturation (95°C, 1 min) annealing (60°C, 1 min), and primer extension (72°C, 2 min). For the specific primers of the gene coding the 27 kDa protein [26], LO (5' CAACTCTCTTGGCTTTGGTTGAAG) and UP (5' CTGTTGTTTCCGTCCTTGCGC), the amplification conditions used this time were the following: initial denaturation (95°C, 5 min), 30 cycles of denaturation (95°C, 1 min), annealing (55°C, 1 min), primer extension (72°C, 7 min). Five microliters of the reaction product were analyzed by electrophoresis on a 0.8% agarose gel in Tris-borate-EDTA buffer with ethidium bromide and visualization under UV light.

## RESULTS

Upon autopsy, the two animals showed no gross lesions in their internal organs. Nonetheless, after 6 weeks of incubation, agar cultures prepared from the minced tissues of the first armadillo, grew several mycelial colonies; these were tan, had short mycelia and adhered strongly to the agar (Figure 2a). Microscopically, the hyphae were thin, septated and thwarted; although intercalary chlamydospores were apparent, no other propagules were visible (Figure 2b). In the liquid medium and in the bottom of the tube, a cottony growth which was formed by hyphae with the same characteristics described above, became visible after six weeks.

Dimorphism was demonstrated when the colonies grown at room-temperature in both the agar and the liquid culture, were transferred to Sabouraud glucose agar with asparagine and thiamine and incubated at 36°C for 10 days. The corresponding cultures were soft, wrinkled and were composed of yeast cells, many of which exhibited the multiple buds that characterize *P. brasiliensis* (Figure 2c). This isolate has been deposited in the ATCC, accession N° 204479.

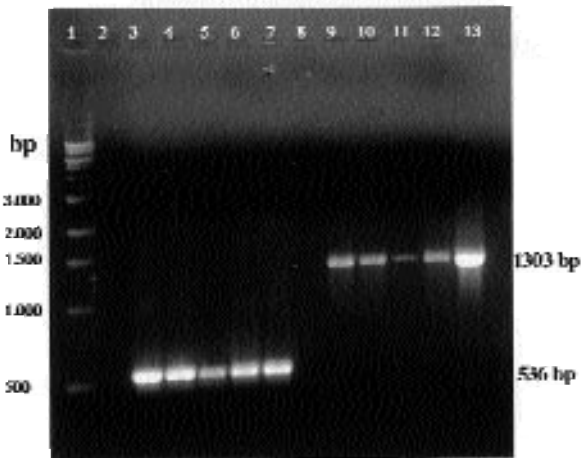


Figure 3. DNA amplification after PCR using *Paracoccidioides brasiliensis* specific primers. Line 1, MW markers; lane 2, negative control; Lane 3 and 13, positive controls (*P. brasiliensis* DNA); Lanes 4, 5, 11, 12, liver; Lanes 6, 7, 9, 10, lymph nodes. Observe bands in the position corresponding to the mesenteric lymph node and the liver of the infected armadillo.

Positive PCR amplification for the 3 sets of primers used, was obtained from the lymph node and the liver of the first armadillos and from the lungs of the mice inoculated with a fragment of the lymph node obtained from the same animal. The corresponding bands of 620 bp for the ITS1-ITS4 primers (data not shown), 1303 bp for the gene of the gp43 and 536 bp for the gene of the p27 are shown in (Figure 3).

The second armadillo proved negative in all tests. All the mice inoculated with the armadillos' viscera proved negative by culture.

## DISCUSSION

To date and with the exception of man, the only other animal in which infection with *P. brasiliensis* has been definitively established by histopathology and isolation from tissues, is the nine-banded armadillo *D. novemcinctus* [10-14]. In the other animals mentioned, the bat [7] and the penguin [8], the fungus has been isolated from the feces but has not been shown in the tissues. As for the squirrel monkey [9], the fungus as it appears in the tissues does not resemble *P. brasiliensis*. The armadillos are amply distributed in Latin America where they occupy areas that coincide, at least partly, with the paracoccidioidomycosis endemic regions [2,10,27].

The first isolations from this mammal were those reported by Naiff *et al.*, who in search for *Leishmania* reservoirs in the Brazilian region of the Amazonas river (State of Pará), surprisingly found four animals infected with the fungus as demonstrated by both histopathology and culture [11]. Further studies by the same group, allowed recovery of the fungus from 18 new armadillos, captured in the same area although in a different locality [12]. These findings were confirmed by Silva-Vergara in one animal captured in the State of Minas Gerais [13] and more recently, by Bagagli *et al.* who found four infected armadillos in the area of Botucatu, São Paulo State [10]. In the latter study, the fungus was cultured from various internal organs, including mesenteric lymph nodes, and also from the hamsters inoculated with the armadillos' tissues. Two new isolations were recently reported in Serra da Mesa, Brasil [14].

It is important to recall that the various areas from which the *P. brasiliensis*-infected armadillos had been

captured, including those in the State of Pará, had previously reported cases of paracoccidioidomycosis, indicating that the areas were endemic for the mycoses [5,28-30]. The same is true for the Colombian zone (Manizales, State of Caldas) where approximately 20 cases have been reported in the last 10 years [15,16].

As shown in Table 1, a total of 81 armadillos have been studied, as reported in the literature, and from these, 29 (35.8%) harbored *P. brasiliensis* in their internal organs. In some of these animals and at time of autopsy, there were gross lesions in some viscera, an indication that active disease and not only subclinical infection, may have occurred [10,11]. In this context, the armadillos should now be considered as regular hosts to *P. brasiliensis*.

Table 1. Natural Infection by *Paracoccidioides brasiliensis* in the nine-banded armadillo *Dasyus novemcinctus*.

Author (year)	Area of capture State, Country	Positive animals (N)	Total studied animals	Ref.
Naiff <i>et al.</i> (1986)	Pará, Brazil	4	20	[11]
Naiff, Barreto (1989)	Pará, Brazil	18	29	[12]
Silva-Vergara (1989)	Minas Gerais, Brazil	1	21	[13]
Bagagli <i>et al.</i> (1998)	São Paulo, Brazil	3	4	[10]
Macedo <i>et al.</i> (1998)	Goiás, Brazil	2	5	[14]
Corredor <i>et al.</i> (1999)	Caldas, Colombia	1	2	*
Total		29	81	
% of positive animals		35.8		

\* Present study

Many circumstances make members of the genus *Dasyus*, important animals for research purposes. For instance, they have a deficient immune system which renders them susceptible to certain chronic microbial infections such as leprosy, and as demonstrated by the Brazilian [10] and the present Colombian experiences, also to paracoccidioidomycosis. These mammals are heterothermic and capable of regulating their metabolism accordingly [31]; furthermore, they are long-lived and as such may develop latent infections [31,32]. Their capacity to excavate the soil at great speed and to depths between 3.5 to 7 meters [31-33], probably allows their exposure to infected aerosols. Alternatively, their alimentary habits which include disturbing ants colonies, uprooting grasses and collecting leaves, may also facilitate and increase such exposure [31-33].

Of interest, the habitat for *D. novemcinctus* spans from the northern part of Mexico, including some of the neighboring southern states of the United States, to Brazil and parts of Argentina [19,34-36]. This distribution coincides partly with the endemic areas for paracoccidioidomycosis [1,28]. Such areas share a certain number of ecological factors, among which the most important ones are high precipitation rates, presence of forests and of abundant water courses, short winters, rainy summers, as well as temperatures between 14°C and 27°C [34-36]. Additionally, in the armadillo's burrows, the environmental changes would be minimal thus increasing the possibilities for a stable fungal microniche such as postulated by Borelli [34].

The finding of naturally infected nine-banded armadillos in Brazil [10-14] and also in Colombia, clearly demonstrate that this mammal is regularly infected with *P. brasiliensis*. Furthermore, in three isolated areas of Colombia surveyed because they were the place of birth and only residence of children with paracoccidioidomycosis, regression analysis revealed that those inhabitants referring contacts with armadillos, had a significantly higher rate of positive reactions to paracoccidioidin. Probably

both man and armadillo share activities in and around the as yet unknown fungal habitat [37].

Our finding of an infected armadillo in Colombia, corroborates previous reports from Brazilian researchers [10-14]. Both the morphological observations and the dimorphic characteristics of the fungus cultured (Figure 2a, 2b), indicate that we are dealing with *P. brasiliensis*. Moreover, the positive PCR amplification from the culture and the organs of the infected armadillo (Figure 3), using specific primers for this particular fungus [25,26], gives further support to fungal identification.

A project designed to determine the armadillos' life pattern within the Colombian paracoccidioidomycosis endemic area where the positive armadillo was captured, is presently underway. The availability of molecular biology techniques such as PCR, may allow the detection of the fungus in environmental samples where there is scarcity of propagules, thus bypassing the requirement for the less effective traditional techniques (animal inoculation, cultures). It is expected that important clues leading to the fungal habitat may thus become apparent so that preventive measures could be implemented.

*This work was supported by COLCIENCIAS Project number 2213-05-386-96. The kind cooperation offered by the personnel in the laboratory and clinical records units of the Hospital Santa Sofía, Manizales, is greatly appreciated. The authors acknowledge the kind reception given to them by the patients and their families. We sincerely thank Prof. W. Chavarriga, Soil Studies Unit, University of Caldas, Manizales for his description of the farm's characteristics.*

## References

- Brummer E, Castaneda E, Restrepo A. Paracoccidioidomycosis: an update. Clin Microbiol Rev 1993;6:89-117.
- Restrepo A. Ecology of *Paracoccidioides brasiliensis*. In: Franco M, Lacaz CS, Restrepo A, Del Negro G (Eds.) Paracoccidioidomycosis, Boca Ratón, CRC Press, 1994.
- Negrón P. El *Paracoccidioides brasiliensis* vive saprofiticamente en el suelo argentino. Prens Med Argentina 1966;53:2381-2382.
- Albornoz M. Isolation of *Paracoccidioides brasiliensis* from rural soil in Venezuela. Sabouraudia 1971;9:248-252.
- Silva-Vergara M, Martínez R, Chada A, Madeira M, Freitas-Silva G, Leite Maffei C. Isolation of a *Paracoccidioides brasiliensis* strain from the soil of a coffee plantation in Ibia, State of Minas Gerais, Brazil. Med Mycol 1998;36:37-42.
- Ferreira M, Freitas L, Lacaz C da S, et al. Isolation and characterization of a *Paracoccidioides brasiliensis* strain from a dogfood probably contaminated with soil in Uberlândia, Brazil. J Med Vet Mycol 1990;28:253-256.
- Grosse E, Tamsitt J. *Paracoccidioides brasiliensis* recovered from the intestinal tract of 3 bats (*Artibeus lituratus*) in Colombia S.A. Sabouraudia 1965;4:124-125.
- Gezuele E. Aislamiento de *Paracoccidioides* sp. de heces de un pingüino de la Antártida. In Proc. IV International Symposium on Paracoccidioidomycosis. Caracas, Venezuela, 1989: Abstract B-2.
- Johnson W, Lang C. Paracoccidioidomycosis (South American blastomycosis) in a squirrel monkey (*Saimiri sciureus*). Vet Pathol 1977;14:368-371.
- Bagagli E, Sano A, Coelho KI, et al. Isolation of *Paracoccidioides brasiliensis* from armadillos (*Dasypus novemcinctus*) captured in an endemic area of paracoccidioidomycosis. Am J Trop Med Hyg 1998;58:505-512.
- Naiff R, Ferreira L, Barrett T, Naiff M, Arias J. Zoonotic paracoccidioidomycosis in armadillos (*Dasypus novemcinctus*) in the State of Para. Rev Inst Med Trop Sao Paulo 1986;28:19-27.
- Naiff R, Barreto T. Novos registros de *Paracoccidioides brasiliensis* em tatus (*Dasypus novemcinctus*). Proc. Congresso Brasileiro Parasitol. Rio de Janeiro, 1989: 197.
- Silva-Vergara M. Contribution to the epidemiological study of paracoccidioidomycosis: a study at a coffee crops area. Rev Soc Bras Med Trop 1997;30:83-84.
- Macedo R, Lacera M, Trilles Reis R, et al. Infecção natural de tatus por *Paracoccidioides brasiliensis* em Serra da Mesa, Minas, Goiás: Estudo preliminar. II Congresso Brasileiro de Micologia. Rio de Janeiro, Brasil, 1998:182.
- Castillo J, Ordoñez N, Lopez S, Castañeda E. Paracoccidioidomycosis. Diagnóstico por el laboratorio de 333 casos. Biomédica 1994;14:230-239.
- Chinchilla M, Kogson M, Insignares R, et al. Valor de las pruebas inmunológicas en el diagnóstico de las enfermedades micóticas: experiencia de un centro de referencia. Biomédica 1997;18:179-184.
- Grisales-García A. Suelos de la zona cafetera. Clasificación y uso. Fondo cultural del Cafetero. Medellín, Colombia, Editorial Bedout, 1977.
- Espinal L. Apuntes Ecológicos, Universidad Nacional de Colombia, Seccional Medellín. Medellín, Editorial Lealon, 1991.
- Roldán G, Velásquez L, Machado T. Ecología: la ciencia del ambiente. Santafé de Bogotá, Norma, 1981.
- Rengifo Diaz E, Orozco Rodriguez J. Fauna nativa: El armadillo. Bogotá: Universidad Nacional, 1995. Colombia, Boletín Técnico; vol 6.
- Restrepo A, Jimenez B. Growth of *Paracoccidioides brasiliensis* yeast phase in a chemically defined culture medium. J Clin Microbiol 1980;12:279-281.
- Bowman B. A model PCR/probe system for the identification of fungal pathogens. In: Persing D, Smith T, Tenover F, White T (Eds.) Diagnostic Molecular Microbiology. Washington DC, American Society for Microbiology, 1993:423-430.
- McEwen J, Garcia A, Ortiz B, Botero S, Restrepo A. In search of the natural habitat of *Paracoccidioides brasiliensis*. Arch Med Res 1995;26:305-306.
- Van Burik J, Schreckhise R, White T, Bowden R, Myerson D. Comparison of 5 extraction techniques for isolation of DNA from filamentous fungi. J Med Mycol 1998;36:299-303.
- Cisalpino P, Puccia R, Yamauchi L, Cano M, da Silveira J, Travassos L. Cloning, characterization, and epitope expression of the major diagnostic antigen of *Paracoccidioides brasiliensis*. J Biol Chem 1996;271:4553-4560.
- McEwen J, Ortiz B, Garcia A, Florez A, Botero S, Restrepo A. Molecular cloning, nucleotide sequencing, and characterization of a 27-kDa antigenic protein from *Paracoccidioides brasiliensis*. Fungal Genet Biol 1996;20:125-131.
- Wanke B, Londero A. Epidemiology and Paracoccidioidomycosis Infection. In: Paracoccidioidomycosis. Franco M, Lacaz CS, Restrepo A, Del Negro G (Eds.), Boca Ratón, FL, CRC Press, 1994.
- Thalhari S, Souza M, Schettini A, Talhari A. Deep Mycoses in Amazon Region. Internal J Dermatol 1988;27:481-484.
- Naiff R, Barrett T, JR A, Naiff M. Encuesta epidemiológica da histoplasmosis, paracoccidioidomycosis y leishmaniasis mediante pruebas cutáneas. Bol Of Sanit Panam 1988;104:35-49.
- Marques S, Franco M, Mendes R, et al. Aspectos epidemiológicos da paracoccidioidomycose na área endêmica de Botucatu (São Paulo-Brasil). Rev Inst Med Trop São Paulo 1983;25:87-92.
- Emmons L, Feer F. Neotropical rainforest mammals. Chicago, The University of Chicago Press, 1990.
- Eisenberg J. Mammals of the neotropics. The Northern Neotropics. Chicago, The University of Chicago Press, 1989.
- Ferguson-Laguna A. El cachicamo sabanero: aspectos de su biología y ecología. Caracas, Fondo Editorial, Acta Científica Venezolana, 1984.
- Borelli D. Algunos aspectos ecológicos de la paracoccidioidomycosis. Proc. Panam. Symp. Paracoccidioidomycosis: Panamerican Health Organization Washington DC, 1972:59-64.
- Restrepo A, Greer D, Moncada L. Relationship between the environment and Paracoccidioidomycosis. Proc. Panam. Symp. Paracoccidioidomycosis: Panamerican Health Organization Washington DC, 1972:84-91.
- Forjas M. Estudo da epidemiologia de paracoccidioidomycose. Rastreamento de áreas endêmicas e de "reservárea" no Brasil [Ph.D. Tesis]. São Paulo, 1989.
- Cadavid D, Restrepo A. Factors associated with *Paracoccidioides brasiliensis* infection among permanent residents of three endemic areas in Colombia. Epidemiol Infect 1993;111:121-133.