

Tabla 1
Hallazgos clinicomicológicos en pacientes con *tinea capitis* variedad seca

Pacientes con <i>Tinea capitis</i>	Evolución	Observación microscópica	Cultivo
1. Niño de 8 años	1 mes	Parasitación mixta	<i>Microsporum canis</i>
2. Niña de 11 años	2 semanas	Parasitación endotrix	–
3. Niña de 4 años	2 meses	Parasitación mixta	–
4. Niño de 7 años	1 mes	Parasitación endotrix	<i>M. canis</i>
5. Niño de 3 años	1 año	Parasitación endotrix	<i>Trichophyton tonsurans</i>
6. Niño de 5 meses	1 mes	Parasitación endotrix	–
7. Niño de 7 años	Desconocido	Parasitación endotrix	<i>T. tonsurans</i>

Fuente; archivos de micología del Centro de Referencia en Micología (CEREMI) (Instituto Dermatológico de Jalisco).

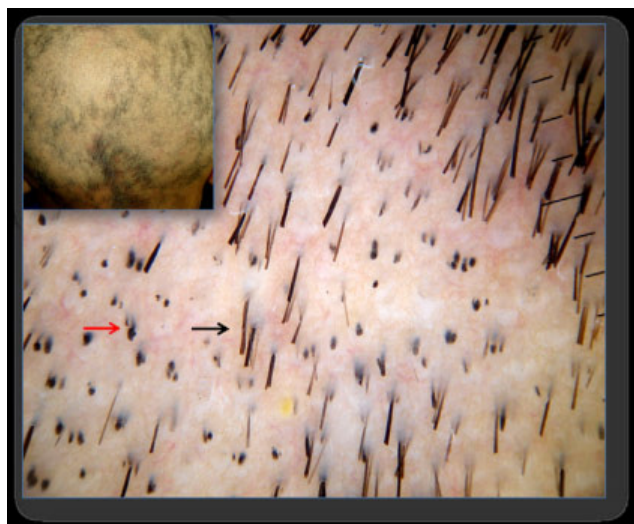


Figura 3. Dermoscopia en alopecia areata con presencia de «pelos en forma de signo de exclamación» (flecha negra) y «pelos cadavéricos» (flecha roja).

Bibliografía

1. Arenas R. Dermatomifosis en México. Rev Iberoam Micol. 2002;19:63–7.
2. Bonifaz A. Dermatomifosis. En: Micología Médica Básica, 3 ed. México DF: Mc Graw Hill Interamericana; 2010. p. 59–99.
3. Ross E, Vincenzi C, Tosti A. Videodermoscopy in the evaluation of hair and scalp disorders. J Am Acad Dermatol. 2006;55:799–806.
4. Slowinska M, Rudnicka L, Schwartz R, Kowalska-Oledzka E, Rakowska A, Sicinska J, et al. Comma hairs: A dermatoscopic marker for Tinea capitis. A rapid diagnostic method. J Am Acad Dermatol. 2008;59(Supl):S77–9.

Ana Beatriz Crocker Sandoval *, José Alfredo Soto Ortiz,
Jorge Mayorga Rodríguez, Alejandro García Vargas y Delfina
Guadalupe Villanueva Quintero

Instituto Dermatológico de Jalisco “Dr. José Barba Rubio”, Centro de
Referencia en Micología Médica, CEREMI, Guadalajara, México

*Autor para correspondencia.
Correo electrónico: anacrocker@hotmail.com
(A.B. Crocker Sandoval).

doi:10.1016/j.riam.2010.02.003

Burden of onychomycosis in rural India: Clinical and mycological assessment of the disease severity using Naildex score

Onicomycosis en la India rural: evaluación clínica y micológica de la enfermedad mediante el sistema de puntuación Naildex

Sr. Director:

Onychomycosis denotes fungal infection of the nail characterized by thickening, splitting, roughening and discoloration of nail and accessory structures due to dermatophytes, non-dermatophyte moulds and few yeast genera.² Onychomycosis can have a lasting adverse impact on patient's daily life, social functioning, physical and mental health; items collectively termed as “Quality of Life”.⁵ The predisposing factors range from advancing age, trauma, geo-climatic conditions, occupation, social class, immune status of the host and associated superficial mycoses like tinea pedis.^{1,3} Naildex score first applied by Warshaw et al.⁶ was used in this study to understand the burden of onychomycosis in agricultural workers in a rural community setting, and to assess the disease severity.

The study was conducted during October 2007 to October 2008 including three coastal villages in Karnataka, Southern India. 42 patients with clinical features of onychomycosis were screened for the disease. The nail and adjacent area was cleaned with 70% alcohol before collection with a nail clipper and tweezers onto pre-sterilized black kraft paper and portioned for KOH-calcofluor microscopy and fungal culture. The nail segments were briskly dipped in methanol to remove any bacterial contaminant and inoculated on Sabouraud dextrose agar with chloramphenicol and cycloheximide and Sabouraud dextrose agar with chloramphenicol and incubated at 28 °C for 3 weeks. Identification of the filamentous/yeast fungi was done based on the macroscopic and microscopic features as per the standard mycological methods. A repeat sample was procured from all those patients who were both microscopy and culture positive case for confirmation of onychomycosis and Naildex score was recorded.

Among the 42 patients screened, 17 were positive by microscopy and culture, and 20 positive by microscopy alone. This included 13 females and 4 males. The results of microscopy and culture positive cases are shown in Table 1. The

Table 1
Summary of onychomycosis cases screened by microscopy and culture

	Microscopy		Total
	Positive	Negative	
Culture			
Positive	17	0	17
Negative	3	22	25
Total	20	22	42

Table 2
Etiological agents involved with confirmed cases of onychomycosis

Etiological agent involved	Site affected	
	Toenail	Fingernail
<i>Trichophyton rubrum</i>	1	0
<i>Trichophyton mentagrophytes</i>	1	1
<i>Fusarium solani</i>	5	1
<i>Acremonium</i> spp.	1	0
<i>Paecilomyces</i>	1	0
<i>Alternaria</i> spp.	2	0
<i>Curvularia lunata</i>	1	1
<i>Candida parapsilosis</i>	0	3

Table 3
Comparison between finger and toenail with duration of onychomycosis

	Score mean \pm S.D.	
	Toenail*	Fingernail**
Duration years		
≤ 5	0.221 \pm 0.098	0.164 \pm 0.010
≥ 6	0.6043 \pm 0.272	0.660 \pm 0.085

* p -value = 0.010.

** p -value = 0.002.

mean age of the females was 52 years and of the males was 49 years. Distal lateral subungual onychomycosis was seen in 9 patients, and 8 patients presented with total dystrophic onychomycosis. Toenails alone were affected in 10 patients, and fingernails only in 6 patients. Toenails and fingernails both were

affected in 1 patient. The commonest isolate from the toenails was *Fusarium solani*, and that from the fingernails was *Candida parapsilosis* (Table 2). Naildex score was calculated for patients who yielded a positive microscopy and culture result. Mean of the scores – toenail and fingernail – was compared with the duration of the disease by the Independent Sample t -test, as depicted in Table 3.

Various scoring methods have been devised to study the disease severity like the Planimetry method and the Global evaluation method.⁴ The Planimetry method is tedious and time consuming and it cannot distinguish minimal residual disease from cure. Both methods are imprecise.⁶ An increase in the score with an increase in duration of the disease was also seen in study done by Warshaw et al.⁶

This study highlights the burden of onychomycosis among agricultural workers in a rural setting. The Naildex scoring method is rapid and inexpensive and may have a significant role for testing new drugs in clinical trials and also may be used to assess the response to treatment of onychomycosis.

References

1. Elewski BE. Onychomycosis: pathogenesis, diagnosis and management. Clin Microbiol Rev. 1998;11:415–29.
2. Ellis DH, Watson AB, Marley JE, Williams TG. Non-dermatophytes in onychomycosis of the toenails. Br J Dermatol. 1997;136:490–3.
3. Faergemann J, Baran R. Epidemiology, clinical presentation and diagnosis of onychomycosis. Br J Dermatol. 2003;149:1–4.
4. Gupta AK, Fleckman P, Baran R. Ciclopirox nail lacquer topical solution 8% in the treatment of toenail onychomycosis. J Am Acad Dermatol. 2000;43: S70–80.
5. Warshaw EM, Foster JK, Cham MH, Grill JP, Chen SC. NailQOL: a quality-of-life instrument for onychomycosis. Int J Dermatol. 2007;46:1279–86.
6. Warshaw EM, Traywick CA, Hoffman AA, Lilly KK, Koshnick RL, Robinson JW, et al. Naildex: pilot evaluation of an onychodystrophy severity instrument. Mycoses. 2007;51:14–20.

Peralam Yegneswaran Prakash ^{a,*}, Gurung Shrijana ^b and Bairy Indira ^b

^a Kasturba Medical College, Manipal University, Manipal, Karnataka, India

^b Microbiology, Manipal University, Manipal, Karnataka, India

*Corresponding author.

E-mail address: prakashpy123@yahoo.co.in
(P. Yegneswaran Prakash).