

Extracutaneous sporotrichosis in a patient with liver cirrhosis

Salvador Fonseca-Reyes¹, Francisco J. López Maldonado¹,
Roberto C. Miranda-Ackerman¹, Ezequiel Vélez-Gómez²,
Paola Álvarez-Iñiguez², Fernando A. Velarde-Rivera³
and E. Patricia Ascensio-Esparza³

¹Department of Internal Medicine, ²Department of Pathology and ³Department of Microbiology, Hospital Civil "Dr. Juan I. Menchaca", Centro Universitario de Ciencias de la Salud, University of Guadalajara, Jalisco, México

Summary We report an unusual case of disseminated cutaneous sporotrichosis with oral mucous and tracheal involvement in a forty-year-old male with a history of heavy drinking and liver cirrhosis. We also review the literature and other similar published cases.

Key words Sporotrichosis, *Sporothrix schenckii*, Liver cirrhosis

Esporotricosis extracutánea en un paciente con cirrosis hepática

Resumen Se presenta el caso clínico de un paciente de 40 años de edad con antecedente de alcoholismo intenso y cirrosis hepática que desarrollo esporotricosis cutánea diseminada con afectación a mucosa oral y tráquea. Se comenta la literatura correspondiente.

Palabras clave Esporotricosis, *Sporothrix schenckii*, Cirrosis Hepática

Sporotrichosis is a granulomatous mycosis caused by the dimorphic soil fungus *Sporothrix schenckii*. Most cases are reported from Mexico [8], Peru [12], Brazil [9], and Uruguay [3]. Other endemic areas are India, Japan [5], and South Africa although recently cases have been reported all over the world. The fungus spreads from the initial lesion along lymphatic vessels, forming indolent nodular and ulcerating lesions restricted to the skin and subcutaneous tissue that typifies the most common form, the lymphocutaneous [3]. Dissemination to other organs and tissues such as mucous membranes, bones, muscles, viscera and central nervous system appears to occur more often in patients with an immunosuppressive condition (eg. alcoholism, diabetes, AIDS). Here we report a case with multifocal cutaneous sporotrichosis lesions with oral mucous and tracheal involvement in a patient with liver cirrhosis.

Case report

A 40 year-old male was admitted to the department of Internal Medicine with fever, dehydration and a disseminated dermatosis. The patient was an iron worker with cirrhosis and a twenty-two year history of heavy drinking. He received a blood transfusion 6 years before because of upper gastrointestinal bleeding due to a gastric ulcer. Two months before, the patient noticed pruritus and painless maculo-papular lesions on his face, neck, trunk, and extremities. He complained ofodynophagia, dysphonia and malaise.

In the physical exam the patient was sleepy and there were no palpable lymph nodes. He had numerous skin lesions involving almost the whole body surface, with exception of hands and feet (Figure 1). Lesions at different stages were seen, but the most prominent were necrotic ulcers, nodules and verrucous plaques, some with golden-yellow crusts with involvement of the prepuce and scrotum. Blood tests revealed microcytic and hypochromic anemia (hemoglobin 7.19 g/dl), creatinine: 1.6 mg/dl, urea: 189 mg/dl, sodium: 153 mmol/l, potassium: 5.5 mmol/l, serum albumin: 1.4 g/dl and total bilirubins of 2.1 mg/dl. He had two negative ELISA for HIV. Treatment was initiated with dicloxacillin 1 g IV every 6 h and fluconazole 100 mg IV every 12 h due to a suspected staphylococci and fungus mixed infection. The hydroelectrolytic imbalance and acute renal failure were corrected. A punch biopsy taken from one skin lesion stained with periodic acid-Schiff showed a mononuclear and polymorphonuclear infiltrate of the dermis, vasculitis of the deep venulo-capillary plexus and pannicular septum that were initially attributed to *Candida* spp. Therapy was changed to Amphotericin B with an initial dose of 25 mg IV and a maintenance dose of 50 mg IV every day.

Corresponding Author:
Dr. Salvador Fonseca Reyes
Enrique Rodo 2921
Prados, Providencia
C.P. 44650 Guadalajara
Jalisco, México
Tel.: +52 33 3654 3304
E-mail salvadorf@mail.hcg.udg.mx

Aceptado para publicación el 10 de abril de 2006

©2007 Revista Iberoamericana de Micología
Apdo. 699, E-48080 Bilbao (Spain)
1130-1406/01/10.00 €

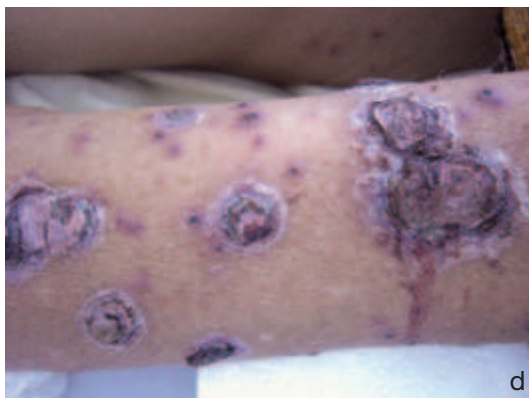
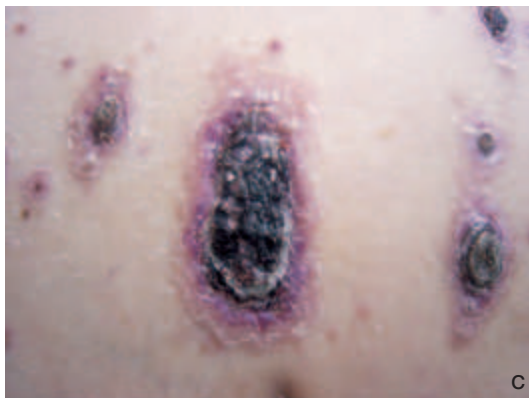
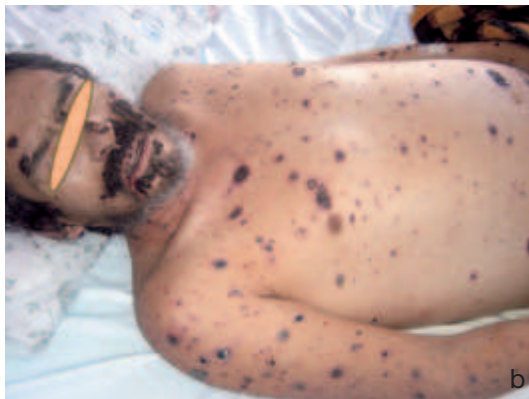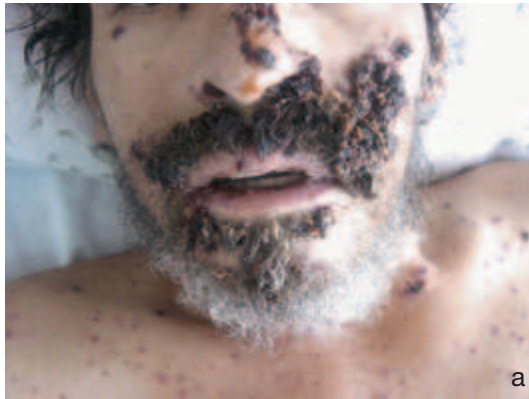Figure 1. a) Verrucous and crust covered coalescing skin lesions on face; b) Multiple lesions at different stages: necrotic ulcers, nodules and verrucous plaques with hematic crusts with redness and desquamation of surrounding skin; c) detail of abdominal skin lesions; d) ulcerated hemorrhagic crusted lesion on arm.

The patient had a torpid evolution and he died after 18 days. A week after the death of the patient, a growth on Sabouraud culture medium demonstrated the presence of *Sporothrix schenckii* (Figure 2A).

Sections of tissue specimens taken at the autopsy were stained with Grocott's methenamine silver and periodic acid-Schiff reagent, and revealed scanty small round and cigar-shaped yeast forms (Figures 2B, 3A and 3B), that were compatible with a mycosis due to sporotrichosis with total skin, tongue, and tracheal involvement. Micro-nodular cirrhosis, acute diffuse alveolar damage in hyaline membrane phase, portal vein thrombosis, and a gastric peptic ulcer with bacterial colonization were also seen.

Discussion

Sporotrichosis is the most important subcutaneous mycosis in Mexico. It commonly presents as lymphocutaneous (75%) and fixed cutaneous (20%) forms [3,4,8]. Disseminated and extracutaneous presentations are uncommon; in a series of 304 cases collected in 36 years in Brazil [9], only 4 corresponded to these types. Others have reported similar findings, where the frequency ranges from 0.5% to 9% [5,12]. Due to the atypical and complex form of this presentation, such as that described here, the term "pyoverruoid syndrome" has been used to describe verrucose and erythematic crust covered lesions of different diseases such as leishmaniasis, chromoblastomycosis, tuberculosis verrucosa cutis, chronic staphylococcal lymphangitis, and also sporotrichosis [2].

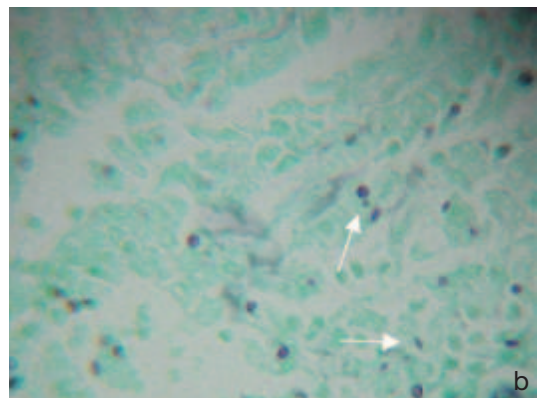
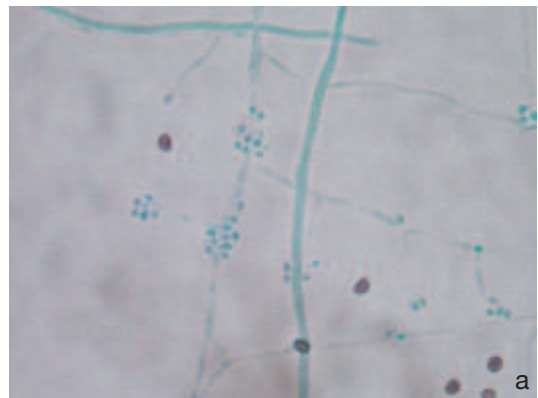


Figure 2. a) Conidia located laterally and at the extreme end of the hyphae observed on one of the lesions grown in Sabouraud medium, 1000x; b) Spherical yeast form and cigar-shaped yeast (arrows) of one of the tongue lesions stained with Grocott's methenamine silver (GMS). 400x. Post-mortem study.

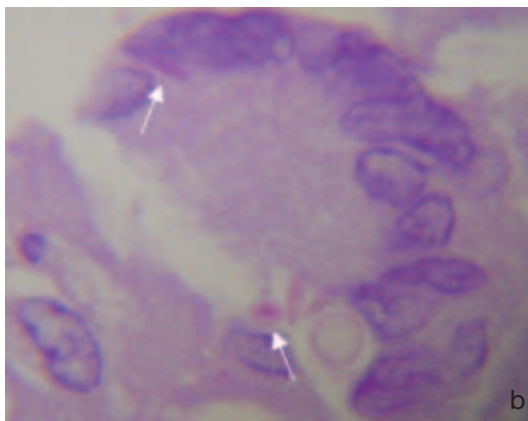
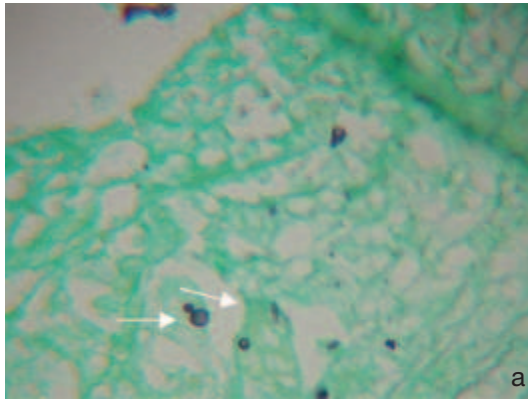


Figure 3. a) Spherical yeast forms and cigar-shaped yeast (arrow) visualized in tracheal specimens that are stained with GMS. 400x; b) Langhans giant cells, containing spherical yeast forms and cigar-shaped yeast of one of the skin lesions stained with periodic acid-Schiff. 400x. Post-mortem study.

It has been reported in immunocompromised patients developing unusual histological and clinical presentations of sporotrichosis, that may be delayed diagnosis for

as much as several months [13]. Diabetes, AIDS, chronic obstructive pulmonary disease, alcoholism and chronic use of steroids appear to be risk factors for the development of extracutaneous and disseminated forms of the disease [3-5,8]. Most cases have been described in alcoholic or cirrhotic patients with or without diabetes [1,7,14]. We believe that alcoholism and cirrhosis were the predisposing factors in this particular case. Mohan and colleagues, in India, [10] reported an alcoholic individual with multifocal Sporotrichosis, with great erythematous edematous necrotic lesions similar to those found in our patient.

Another interesting consideration was the dysphonia and odynophagia referred by the patient, which together with the histopathological report of *S. schenckii* and the macroscopic involvement of tongue and trachea confirm the dissemination of the fungus to the respiratory tract. This type of involvement is even more rare and has been observed in patients with or without skin lesions but with severe immunocompromise and with the use of inhaled corticoids [6,16].

Without a doubt, one of the difficulties in the diagnosis of sporotrichosis is the few yeast cells on direct exam or biopsy specimens [4,7]. The demonstration of the fungi in tissue segments is very difficult and has even been confused with other mycosis such as cryptococcosis, histoplasmosis and candidiasis [15,16]. The use of more specific stains such as periodic acid-Schiff, Grocott's methenamine-silver, or immunohistochemical stains, (Figures 2B, 3A y 3B) have higher rates in demonstrating the typical forms of the microorganism, even more so when there is a high index of suspicion or clinical acuity [11]. The best diagnostic method is the culture of affected tissue on Sabouraud medium that permits the observation of typical *S. schenckii*; pigmented hyphae with branches of microconidia similar to a flower.

Finally, although rarely life threatening, the treatment response to disseminated or extracutaneous sporotrichosis is poor, especially in the immunosuppressed individual. Unfortunately, beside the disseminated mycosis, these patients suffer from a variety of different immunosuppression-related ailments, which ultimately cause their death.

References

- Baker JH, Goddpasture HC, Kuhns HR Jr, Rinaldi MG. Fungemia caused by an amphotericin B-resistant isolate of *Sporothrix schenckii*. Successful treatment with itraconazole. Arch Pathol Lab Med 1989; 113: 1279-1281.
- Borelli D. Esporotricosis. Derm Venz 1964; 4: 89-105.
- Conti-Díaz IA. Epidemiology of sporotrichosis in Latin America. Mycopathologia 1989; 108: 113-116.
- Espinosa-Texis A, Hernández-Hernández F, López-Martínez R, Lavalle P, Barba-Rubio J. Estudio de 50 pacientes con esporotricosis. Evaluación clínica y de laboratorio. Gac Med Mex 2001; 137: 111-116.
- Itoh M, Okamoto S, Kariya H. Survey of 200 cases of sporotrichosis. Dermatologica 1986; 172: 209-213.
- Khabie N, Óbice TG, Roberts GD, Thompson DM. Laryngeal sporotrichosis causing stridor in a young child. Int J Pediatr Otorhinolaryngol 2003; 67: 819-823.
- Kusuhara M, Hachisuka H, Sasai Y. Statistical survey of 150 cases with sporotrichosis. Mycopathologica 1988; 37: 101-103.
- Mayorga-Rodríguez JA, Barba-Rubio J, Muñoz-Estrada VF, Rancel CA, García VA, Magaña CI. Sporotrichosis in Jalisco state: a clinical-epidemiological study (1960-1996). Dermatol Rev Mex 1997; 41: 105-108.
- Michel da Rosa A, Scroferneker M, Vettorato R, Lopes R, Vettorato G, Weber A. Epidemiology of sporotrichosis: A study of 304 cases in Brazil. J Am Acad Dermatol 2005; 52: 451-459.
- Mohan N, Jayaseelan E, Abraham A, Rajendran S, Stephen J, Sharief S, Macaden R. Cutaneous sporotrichosis in Bangalore, southern India. Int J Dermatol 2004; 43: 269-272.
- Morris R. Sporotrichosis. Clin Exp Dermatol 2002; 27: 427-443.
- Pappas PG, Tellez I, Deep A, Nolasco D, Holgado W, Bustamante B. Sporotrichosis in Peru: description of an area of hyperendemicity. Clin Infect Dis 2000; 30: 65-70.
- Rocha MM, Dassin T, Lira R, Lima EL, Severo LC, Londero AT. Sporotrichosis in patient with AIDS: report of a case and review. Rev Iberoam Micol 2001; 18: 133-136.
- Sacks P, Fellner SK. Recurrent reversible acute renal failure from amphotericin. Arch Intern Med 1987; 147: 593-595.
- Sharma NL, Majan VK, Verma N, Thakur S. Cutaneous sporotrichosis: An unusual clinico-pathologic and therapeutic presentation. Mycoses 2003; 46: 515-518.
- Zhou H, Asunción A, Love GL. Laryngeal and respiratory tract sporotrichosis and steroid inhaler use. Arch Pathol Lab Med 2003; 127: 893-894.