

# Disseminated cryptococcosis in an AIDS patient with unusual clinical presentation

Somansu Basu<sup>1</sup>, Puneet Jain<sup>2</sup>, Sajid Ansari<sup>1</sup>, Sumaya Salem Al-Arimi<sup>2</sup> & SK Singh<sup>3</sup>

<sup>1</sup>Department of Microbiology, <sup>2</sup>Department of Pathology and <sup>3</sup>Department of Medicine, Sur Hospital, Ministry of Health, Oman

**Summary** Disseminated cryptococcosis is a rare and often fatal disease. Here in we report an unusual fatal case of disseminated cryptococcosis. The patient presented with a past history of postmenopausal bleeding with loss of consciousness, altered mental status, few seizures and a low grade fever. Lumbar puncture revealed elevated pressure, lymphocytic pleocytosis, elevated protein and markedly reduced glucose level. *Cryptococcus neoformans* was isolated from cerebrospinal fluid and blood. Serological assay revealed the presence of human immunodeficiency virus. The patient was treated with antifungal agents intravenously without any signs of improvement and the patient passed away after two weeks of therapy. This is the first case report of disseminated cryptococcosis in an AIDS patient suffering from cryptococcal vaginitis.

**Key words** Disseminated cryptococcosis, Vaginitis, AIDS

## Criptococosis diseminada en un paciente con sida con presentación clínica excepcional

**Resumen** La criptococosis diseminada es una enfermedad poco común y, a menudo, fatal. Los autores presentan el caso de una mujer con esta enfermedad. El historial de la paciente incluía sangrado posmenopáusico, pérdida del conocimiento, alteración de la conciencia, ataques y febrícula. La punción lumbar reveló presión alta del líquido cefalorraquídeo, pleocitosis linfocitaria, tasas elevadas de proteínas y bajos niveles de glucosa. *Cryptococcus neoformans* fue aislado en líquido cefalorraquídeo y sangre. Un análisis serológico reveló la presencia del virus de la inmunodeficiencia humana. La paciente fue tratada con agentes antimicóticos por vía intravenosa, sin observarse mejoría, y falleció tras dos semanas de tratamiento. Este es el primer caso de criptococosis diseminada en una paciente con sida y vaginitis criptocócica.

**Palabras clave** Criptococosis diseminada, Vaginitis, Sida

*Cryptococcus* is the second most common opportunistic fungal pathogen after *C. albicans* causing symptomatic cryptococcosis in 8.5% of HIV infected individual [9]. It is an encapsulated yeast acquired by inhalation with a strong tropism for the central nervous system [3]. In immunocompromised individuals, particularly in AIDS patients, it is the most common fungal pathogen causing

central nervous system infection [7,8,11]. Cryptococcal meningitis is a lethal fungal infection prevalent worldwide [4]. To the best of our knowledge, after reviewing the literature, there is no report of disseminated cryptococcosis in an undiagnosed AIDS patient having cryptococcal vaginitis.

### Clinical case

A 45 year old married female presented in Gynaecology OPD on 15/10/06 with two years history of postmenopausal bleeding and lower abdominal pain along with intermittent vaginal discharge. She complained of post-coital bleeding during all this period. On speculum examination cervix was found flushed with vagina. A small ulcer was found at 3 O'clock position that bled on touch. No vaginal discharge was observed. Pelvic examination revealed mobile uterus, fornix free but scarred left sided vaginal vault. Pelvic scan showed uterus small with a thin midline streak measuring 4 mm. There was apparently no involvement of parametrium. No free fluid was seen in the pelvis and no pelvic lymphadenopathy was present. The routine

**Address for correspondence:**  
Dr. Somansu Basu  
Sur Hospital, Ministry of Health  
PO Box 346, Postal Code 411, Sur  
Sultanate of Oman  
Tel.: +968 25561550  
Fax: +968 25561558  
E-mail: somansu@rediffmail.com

Aceptado para publicación el 25 de abril de 2008

©2008 Revista Iberoamericana de Micología  
Apdo. 699, E-48080 Bilbao (Spain)  
1130-1406/01/10.00 €

papanicolau (PAP) smear revealed dysplasia with koilocytosis. The punch biopsy of the vagina exhibited tissues segments lined by stratified squamous epithelium. The underlying stroma was oedematous and lined by foamy histiocytes within which there were several encapsulated organisms which stained positive with periodic acid Schiff stain (PAS). Mucocarmine stain showed the pink mucinous capsule and budding yeast cells (Figure). These findings were compatible with cryptococcal vaginitis. Two months later she was brought to Accident and Emergency department with history of loss of consciousness and altered sensorium. On general examination she was sick looking, hypertensive (166/106mm Hg) without fever. Respiratory and cardiovascular system examination was found normal. Central nervous examination showed right sided facial palsy, less movement of left side, obliteration of right nasolabial fold. Both the plantar reflex was showing extensor response. Pupils were equal and normal reacting. Laboratory findings revealed neutrophilic pleocytosis (78.6%), elevated blood glucose level (8 mmol/l) along with proteinuria. Liver function test, renal function test, lipid profile and clotting factor were normal. The CT scan brain revealed slight atrophic changes in cerebrum. Chest X ray was found normal. Serological studies demonstrated the presence of HIV antibodies for the first time and HIV viral load was 74,000 copies/mm<sup>3</sup>. The CD4 count was <100/mm<sup>3</sup> and CD4/CD8 ratio was < 0.3. Cerebrospinal fluid (CSF) analysis showed increased pressure, decreased glucose level (3.1mmol/l), increased protein level (119.5mg/dl) and a total cells count of 950/cmm. CSF bacterial latex test was negative. Serological tests for cryptococcal antigen showed positive result with a titer of 1:1024. On the CSF gram stain exhibited gram positive budding yeast cells. India ink preparation showed encapsulated budding yeast cells. The CSF culture on Sabouraud dextrose agar (Oxoid, UK), 1.5-2 mm moist, creamy, convex, circular opaque yeast like colonies grew, and *Crypto-*

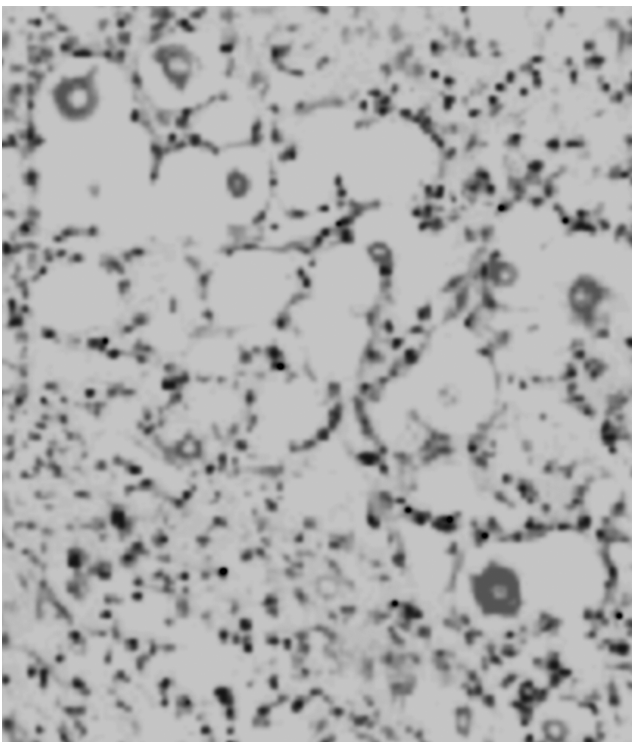


Figure. Numerous pink encapsulated yeast cells within foamy histiocytes in vaginal histology.

*coccus neoformans* identification was confirmed by API 20 C (bioMérieux, France). The organism was also isolated from blood simultaneously. The minimum inhibitory concentration performed according to standard CLSI (formerly NCCLS) guidelines [10] showed susceptibility to amphotericin B (0.50 mg/l), fluconazole (8 mg/l) and flucytosine (16 mg/l). Intravenous liposomal amphotericin B (1 mg/kg/ day) and fluconazole 200 mg/bd were started immediately. Antiretroviral drugs (HAART) were introduced. However, the patient failed to respond to the therapy and passed away within ten days of admission.

## Discussion

*Cryptococcus neoformans* is an encapsulated basidiomycetous yeast found commonly throughout the world in bird excreta, mainly pigeon droppings [6]. Most of the human cases of cryptococcal infection are airborne acquired. In the present case the source of infection was unclear as there was no history of exposure. Immunocompromised people, as reported by Chakravarti et al. [1], are more susceptible to cryptococcal infection. Skin and genital infections with *Cryptococcus neoformans* are a very rare form of cryptococcosis. Chen et al. reported a suspected case of cryptococcal vaginitis diagnosed histologically in a case of colon cancer [2]. In our case the patient presented with postmenopausal bleeding with an ulcerated lesion in the vaginal vault, which aroused the suspicion of malignancy. The vaginal histology, however, demonstrated encapsulated yeast cells which is consistent with vaginitis.

The patient was found to be suffering from AIDS only after the diagnosis of cryptococcal vaginitis. The pathogenesis is uncertain but probably the primary focus of infection might be lungs, from which due to immunocompromised state of the patient, the organism gradually was spread through blood stream into central nervous system, for which it has a natural predilection, and also into vagina. The patient subsequently deteriorated very rapidly and developed signs of meningoencephalitis and deficient functioning of central nervous system in the later stage. Neurological sequels like involvement of cranial nerves are more common in immunocompetent patients [12]. In this patient, however, we observed serious neurological deficits along with seventh nerve palsy. The CT scan also revealed slight degenerative changes that point towards the long standing sub-clinical HIV infection of the central nervous system. The organism was recovered from cerebrospinal fluid and blood simultaneously, indicating dissemination of the yeast inside the body. The patient did not show any kind of skin involvement, lymph nodes, lungs, liver or spleen. In a study involving 822 cases of disseminated cryptococcosis it was reported that incidence of generalized lymphadenopathy, hepatosplenomegaly, urinary tract, respiratory tract involvement and skin lesion are rarely seen [5].

This patient therefore draws considerable attention due to its rare presentation as a case of cryptococcal vaginitis in a disseminated infection. There is no previous report of disseminated cryptococcosis in an AIDS patient along with cryptococcal vaginitis. The differential diagnosis of postmenopausal bleeding usually includes malignancy or other gynaecological disease. With our present knowledge it is therefore important to include opportunistic cryptococcal infections as well.

*The authors are very grateful to the Executive Director of Sur Hospital and the laboratory staff of the Department of Microbiology for their support.*

## References

1. Chakrabarti A, Sharma A, Sood A, Grover R, Sakhuja V, Prabhakar S. Changing scenario of cryptococcosis in a tertiary care hospital in north India. *Ind J Med Res* 2000; 112: 56-60.
2. Chen CK, Chang DY, Chang SC, Lee EF, Huang SC, Chow SN. Cryptococcal infection of vagina. *Obstet Gynecol* 1993; 81: 867-869.
3. Choudhary MW, Sardana K, Kumar P, Diwan V, Anand VK. Disseminated infection with *Cryptococcus neoformans* var. *neoformans* in an 8 years immunocompetent girl. *Ind J Paed* 2005; 72: e1-e3.
4. Currie BP, Cassadeval A. Estimation of prevalence of cryptococcal infection among patients infected with human immunodeficiency virus in New York City. *Clin Infect Dis* 1994; 19: 1029-1033.
5. Dromer F, Mathoulin S, Dupont B, Laporte A. Epidemiology of cryptococcosis in France: a 9 year survey (1985-1993). *Clin Infect Dis* 1996; 23: 82-90.
6. Ellis DH, Pfeiffer TJ. Ecology, life cycle, and infectious propagule of *Cryptococcus neoformans*. *Lancet* 1990; 336: 923-925.
7. Khanna N, Chandramuki A, Desai A, Ravi V. Cryptococcal infections of the central nervous system: an analysis of predisposing factors, laboratory findings and outcome in patients from South India with special reference to HIV infection. *J Med Microbiol* 1996; 45: 376-379.
8. Khanna N, Chandramuki A, Desai A, Ravi V, Santosh V, Shankar SK. Cryptococcosis in the immunocompromized host with special reference to AIDS. *Ind J Chest Dis Allied Sci* 2000; 42: 311-315.
9. Lakshmi V, Sudha T, Teja VD, Umabala P. Prevalence of central nervous system cryptococcosis in human immunodeficiency virus reactive hospitalized patients. *Ind J Med Microbiol* 2007; 25: 146-149.
10. National Committee for Clinical Laboratory Standards. Reference method for broth dilution antifungal susceptibility testing of yeasts. Approved standard M 27-A National Committee for Clinical Laboratory Standards, Wayne, PA, 2002.
11. Oursler KA, Moore RD, Chaisson RE. Risk factors for cryptococcal meningitis in HIV-infected patients. *AIDS Res Hum Retroviruses* 1999; 15: 625-631.
12. Rozenbaum R, Goncalves AJR. Clinical epidemiological study of 171 cases of cryptococcosis. *Clin Infect Dis* 1994; 18: 369-380.