



## Note

### Genital microsporidiosis in women with AIDS: A post-mortem study

Griselda Torres<sup>a</sup>, Fernando Izquierdo<sup>c</sup>, Virginia Capó<sup>a,\*</sup>, Ledy X. López<sup>a</sup>, María C. López<sup>a</sup>, Daniel Limonta<sup>b</sup>, Soledad Fenoy<sup>c</sup>, Carmen Del Águila<sup>c</sup>, Fernando J. Bornay-Llinares<sup>d</sup>

<sup>a</sup> Department of Pathology, Institute of Tropical Medicine Pedro Kourí, Havana, Cuba

<sup>b</sup> Department of Virology, Institute of Tropical Medicine Pedro Kourí, Havana, Cuba

<sup>c</sup> Laboratory of Parasitology, Faculty of Pharmacy, University San Pablo-CEU, Madrid, Spain

<sup>d</sup> Department of Parasitology, University Miguel Hernández, Alicante, Spain

#### ARTICLE INFO

##### Article history:

Received 10 May 2011

Accepted 19 April 2012

Available online 1 May 2012

##### Keywords:

AIDS

Immunohistochemistry

Microsporidia

Disseminated microsporidiosis

Post-mortem

Female reproductive tract

#### ABSTRACT

**Background:** Microsporidiosis is a life threatening opportunistic infection of AIDS patients. The infection is usually restricted to specific anatomical areas, but could become systemic depending on the involved species. Genital microsporidiosis in female patients is rare.

**Objective:** To report genital microsporidiosis in female AIDS patients.

**Methods:** Tissues samples from the genital tract (ovary, fallopian tubes and uterus) of eight deceased women who died of wasting syndrome associated to AIDS and disseminated microsporidiosis at the Institute of Tropical Medicine Pedro Kourí were collected between 1997 and 2005. Using an indirect immunohistochemistry assay the microsporidia species involved in those cases were identified.

**Results:** We report several cases of microsporidial infection of the female genital tract. Six out of eight women with the disseminated form of the disease showed the presence of microsporidia in the genital tract. *Encephalitozoon cuniculi* and *Encephalitozoon hellem* were identified in the internal lining epithelium of the fallopian tubes and endometrium.

**Conclusions:** Microsporidia species could disseminate to other organs and become systemic in severe immunocompromised cases. To our knowledge this is the greatest number of female genital tract microsporidiosis cases so far reported in humans.

© 2011 Revista Iberoamericana de Micología. Published by Elsevier España, S.L. All rights reserved.

### Microsporidiosis genital en mujeres con sida: hallazgos post-mortem

#### RESUMEN

**Antecedentes:** La microsporidiosis es habitualmente una enfermedad oportunista fatal para los pacientes con sida y puede producir una infección localizada o sistémica en función de la especie infectante. La infección del tracto genital femenino por microsporidiosis ha sido escasamente reportada en la literatura.

**Objetivos:** Describir las especies de microsporidiosis en el tracto genital femenino.

**Métodos:** Se analizaron muestras de tejidos provenientes del aparato reproductor (ovario, trompa uterina y útero) de ocho mujeres fallecidas con síndrome de desgaste asociado al sida y microsporidiosis diseminada, en el período de 1997 a 2005 en el Instituto de Medicina Tropical Pedro Kourí. Para la identificación de las especies de microsporidiosis se utilizaron anticuerpos específicos mediante la técnica de inmunohistoquímica indirecta.

**Resultados:** Se describe la infección por microsporidiosis en el tracto genital femenino. De las ocho mujeres estudiadas con la forma diseminada de estos parásitos, seis presentaron microsporidiosis en el tracto genital. Se identificaron *Encephalitozoon cuniculi* y *Encephalitozoon hellem* en el epitelio de revestimiento de la luz de trompas de Falopio y en endometrio.

##### Palabras clave:

SIDA

Inmunohistoquímica

Microsporidiosis

Microsporidiosis diseminada

Post-mortem

Aparato reproductor femenino

\* Corresponding author.

E-mail address: [vcapo@ipk.sld.cu](mailto:vcapo@ipk.sld.cu) (V. Capó).

**Conclusiones:** Algunas especies de microsporidios pueden diseminarse a diversos órganos, especialmente cuando hay una profunda inmunodeficiencia como ocurre con el sida terminal. Según la literatura revisada esta es la mayor casuística recopilada de microsporidiosis genital.

© 2011 Revista Iberoamericana de Micología. Publicado por Elsevier España, S.L. Todos los derechos reservados.

Microsporidiosis is an opportunistic and life threatening infection in AIDS patients and in severely immunocompromised patients.<sup>6,19</sup> Microsporidiosis has been described in several anatomical locations. However, only one report of this infection affecting the female genital tract has been so far diagnosed.<sup>18</sup>

Microsporidia species are obligate intracellular parasites recently placed within the Kingdom Fungi.<sup>10</sup> However, the available data are not conclusive and more analyses have to be conducted to validate those claims.<sup>14,15</sup> Four species have been frequently reported infecting humans (i.e., *Enterocytozoon bieneusi*, *Encephalitozoon intestinalis*, *Encephalitozoon cuniculi*, and *Encephalitozoon hellem*).<sup>20</sup> Microsporidiosis can be diagnosed using histological preparations, but monoclonal antibodies or molecular methods are required for the species identification.<sup>2,4</sup> The proper identification of microsporidia species is essential to indicate the treatment.<sup>5</sup>

## Materials and methods

Between 1997 and 2005 eight women out of sixty evaluated patients were diagnosed *post-mortem* with disseminated microsporidiosis at the Institute of Tropical Medicine Pedro Kourí (IPK). These women had died with wasting syndrome and disseminated microsporidiosis associated to AIDS. *Post-mortem* tissues samples from ovary, Fallopian tubes and uterus were analysed and processed following standard histological techniques for the identification of microsporidia species described elsewhere.<sup>1</sup> Rabbit polyclonal antibodies anti-*E. intestinalis*, *E. cuniculi* and *E. hellem*, at 1:1600 dilution and mouse monoclonal antibodies anti-*E. bieneusi* and anti-*E. intestinalis*<sup>12,17</sup> at 1:1000 dilution were used as primary antibodies. Microsporidial IHC positive controls involved paraffin-included human tissues previously studied by transmission electron microscopy. Negative controls comprised both, necropsy tissues samples from immunocompetent subjects who died of causes other than microsporidiosis, and tissues samples of the eight evaluated women omitting the primary antibody to detect background staining. The presence of human cytoqueratine was used as an internal control to prove the good tissue condition after the fixation process.

## Results

From the eight patients with disseminated microsporidiosis, six had their genital tract affected. Interestingly, the ovary of these women was the only unaffected organ. The Fallopian tube was the most frequently affected organ (4/6), followed by the endocervix (3/6) and the endometrium (2/6).

Briefly, the tubes were symmetrically affected with a mild increase in their thickness and a light brown colour. The exocervix (3/6) and vagina (1/6) mucosa showed small reddish areas. The endometrial lining was tender and reddish (2/6). In one of the studied women, the tube and ovaries were immersed in a severe peritoneal inflammatory reaction due to a sigmoid perforation in the intestinal wall caused by one of the microsporidia species.

Histologically, chronic salpingitis with neutrophils and a diffuse infiltrate of macrophages within both the thickened mucosal plicae and the lumen was found (Fig. 1A). With haematoxylin and eosin staining lining epithelial cells and macrophages containing

numerous ovoid structures (spores), suggestive of microsporidial infection, were observed (Fig. 1C).

These spores were also detected in all studied subjects in the renal tubular epithelium, adrenal cortex cells, small and large intestine mucosa, cardioesophageal mucosa, medium size bronchial mucosa, as well as within the hepatocytes, pneumocytes, cardiomyocytes, lymph nodes and thyroid acini epithelial cells.

With IHC techniques, the spores within the epithelial cells lining the genital female tract were identified as either *E. cuniculi* or *E. hellem* species (Fig. 1B and D–H).

Numerous spores were immunodetected within the epithelial cells of the patient's mucous membranes. They were immersed in a mild chronic inflammatory infiltrate with the presence of few neutrophils. The spores were also found within the endothelial blood vessels as well as inside the phagocytic cells, and few were located extracellularly within organs lumina.

## Discussion

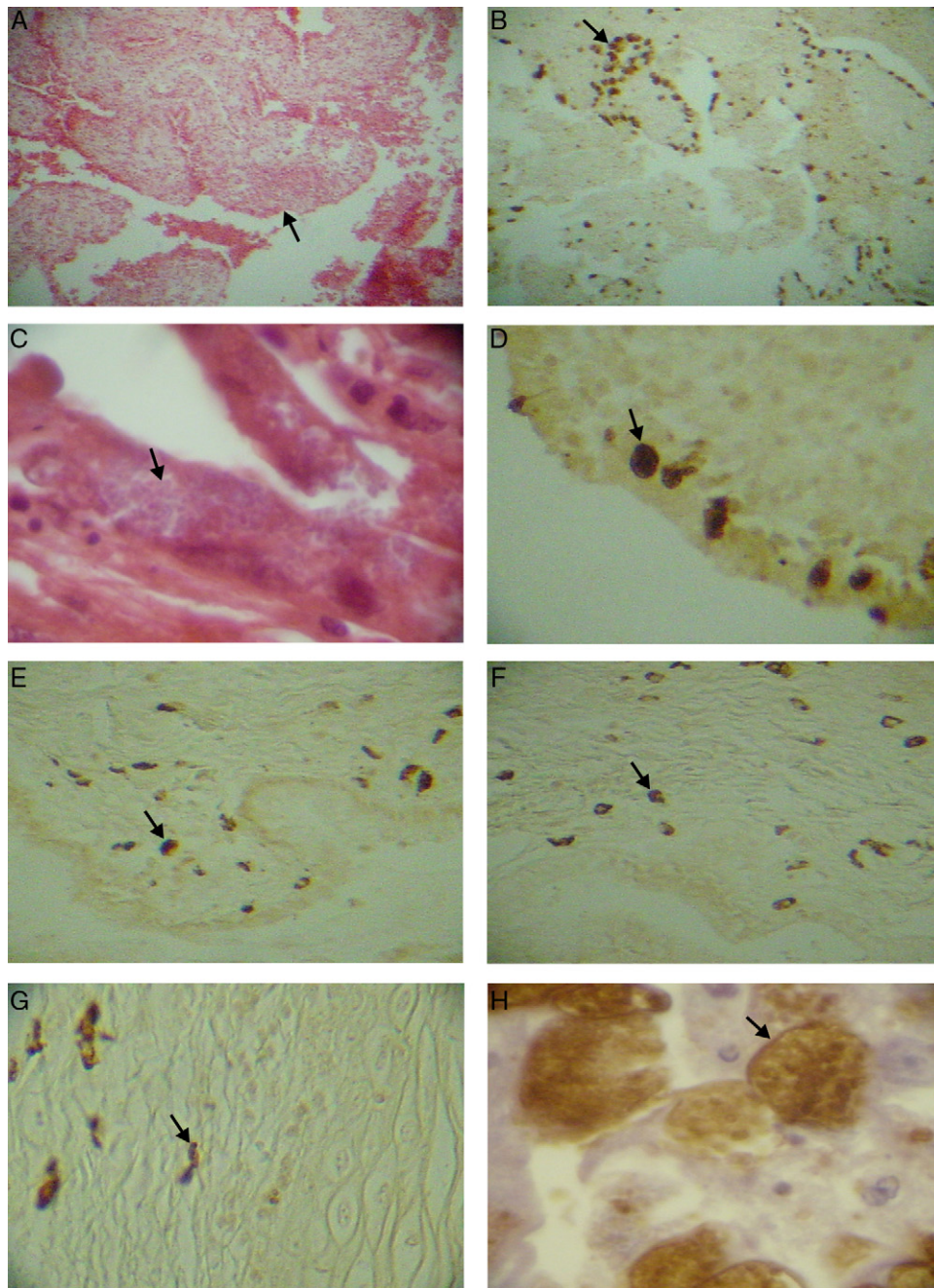
In this study, microsporidia spores were observed inside macrophages in several organs including the lymph nodes and vascular endothelium. The location of the spores at these specific sites suggests that this could be related with their propagation, as previously reported.<sup>9</sup>

Some authors<sup>7</sup> proposed that mononuclear phagocytes may play an important role in the dissemination of the pathogen, by escaping from the intracellular degradation within naïve macrophages. Macrophages require activation signs of Th1 cells to increase their intracellular microbicide effects. This has been shown to be hindered in AIDS patients, who have significantly low numbers of CD4+ T cell lymphocytes.<sup>13</sup> Thus, it has been suggested that the infected macrophages may induce a citoquine gradient for the recruitment of additional macrophages that would become proliferating stores and vehicles for the dissemination of pathogenic microbes.<sup>8</sup>

Another factor that may have influence in the dissemination of pathogens is the type of infecting microsporidia species. The two species found in this study, *E. cuniculi* and *E. hellem*, are related to the disseminated form of the infection.<sup>7</sup> Although a crossed reactivity of the polyclonal antibodies used cannot be discarded, the possibility of co-infection with two microsporidia species may be possible as reported by others.<sup>11</sup>

Only one case of microsporidia affecting the ovaries has been found in the revised literature.<sup>18</sup> According to a report, microsporidia infection in HIV/AIDS patients has a moderate incidence in Cuba.<sup>3</sup> Once antiretroviral therapy (ARV) was supplied to AIDS patients in 2001, microsporidiosis has almost disappeared as cause of death. This impact can be attributed to the restoration of T cell-mediated immunity and to the possible direct antiparasitic activity of some components of ARV (i.e., protease inhibitors).<sup>16</sup>

Microsporidiosis have rarely been considered in the differential diagnosis of opportunistic infections in AIDS. However, an explanation to the relatively high number of cases found in our series may be related to the fact that autopsies are performed in our institution in 75% of all deceased patients. Therefore, the probability of finding microsporidia spores in this type of samples greatly increased the probabilities.



**Fig. 1.** (A) Low magnification microphotograph of the fallopian tube mucosa with thickened plicae (arrow), H/E 6 $\times$ . (B) Immunodetection of *E. cuniculi* in the fallopian tube mucosa (arrow), IHQ 6 $\times$ . (C) Microsporidial parasitophorous vacuoles in fallopian tube mucosa (arrow), H/E 40 $\times$ . (D) *E. hellem* parasitophorous vacuoles in the superficial epithelial layer of endometrium (arrow), IHQ 20 $\times$ . (E) and (F) *E. cuniculi* parasitophorous vacuoles within macrophages located in the cervix stroma underneath the columnar epithelium (arrow), IHQ 20 $\times$ . (G) *E. cuniculi* parasitophorous vacuoles in the exocervix stroma underneath the squamous epithelium (arrow), IHQ 20 $\times$ . (H) High resolution under oil photomicrograph showing *E. hellem* parasitophorous vacuoles (arrow), IHQ 100 $\times$ .

## Conclusion

These findings suggest that microsporidia could disseminate to other organs in cases of severe immunodeficiency. The six studied patients represent the larger number of females with tubular genital tract involvement, so far reported.

## Acknowledgements

This research was partially supported by the Generalitat Valenciana.

## References

1. Boenisch T, Farmilo A, Stead R, Key M, Atwood K. In: Boenisch T, editor. Immunohistochemical staining methods. 3rd ed. California: DakoCytomation; 2001.
2. Bornay-Llinares FJ, da Silva AJ, Moura H, Schwartz DA, Visvesvara GS, Pieniazek NJ, et al. Immunologic, microscopic, and molecular evidence of *Encephalitozoon intestinalis* (*Septata intestinalis*) infection in mammals other than humans. *J Infect Dis.* 1998;178:820–6.
3. Capó V, Barrero M, Velázquez B, Luzardo C, Martínez A, Alujas Z. Diagnosis of coccidia and microspores in specimens of diarrheal feces from first report of microspores in Cuba. *Rev Cubana Med Trop.* 2003;55:14–8.
4. del Aguila C, Croppo GP, Moura H, Da Silva AJ, Leitch GJ, Moss DM, et al. Ultrastructure, immunofluorescence, western blot, and PCR analysis of eight isolates of *Encephalitozoon* (*Septata*) *intestinalis* established in culture from sputum and

- urine samples and duodenal aspirates of five patients with AIDS. *J Clin Microbiol.* 1998;36:1201–8.
5. Didier ES, Maddy JA, Brindley PJ, Stovall ME, Didier PJ. Therapeutic strategies for human microsporidia infections. *Expert Rev Anti Infect Ther.* 2005;3:419–34.
  6. Didier ES, Weiss LM. Microsporidiosis: current status. *Curr Opin Infect Dis.* 2006;19:485–92.
  7. Fischer J, Tran D, Juneau R, Hale-Donze H. Kinetics of *Encephalitozoon* spp. infection of human macrophages. *J Parasitol.* 2008;94:169–75.
  8. Fischer J, West J, Agochukwu N, Suire C, Hale-Donze H. Induction of host chemotactic response by *Encephalitozoon* spp. *Infect Immun.* 2007;75:1619–25.
  9. Franzen C. How do microsporidia invade cells? *Folia Parasitol (Praha).* 2005;52:36–40.
  10. Gill EE, Fast NM. Assessing the microsporidia-fungi relationship: combined phylogenetic analysis of eight genes. *Gene.* 2006;375:103–9.
  11. Graczyk TK, Johansson MA, Tamang L, Visvesvara GS, Moura LS, DaSilva AJ, et al. Retrospective species identification of microsporidian spores in diarrheic fecal samples from human immunodeficiency virus/AIDS patients by multiplexed fluorescence in situ hybridization. *J Clin Microbiol.* 2007;45:1255–60.
  12. Izquierdo F, Fenoy S, del Aguila C. Obtención de anticuerpos monoclonales frente a *Encephalitozoon intestinalis*. *Acta Parasitol Port.* 2001;8:309.
  13. Janeway C, Travers P, Walport M, Shlomchik M. *Immunobiology: the immune system in health and disease.* 6th ed. New York: Garland Science; 2005.
  14. Koestler T, Ebersberger I. Zygomycetes, microsporidia, and the evolutionary ancestry of sex determination. *Genome Biol Evol.* 2011;3:186–94.
  15. Lee SC, Corradi N, Doan S, Dietrich FS, Keeling PJ, Heitman J. Evolution of the sex-related locus and genomic features shared in microsporidia and fungi. *PLoS One.* 2010;5:e10539.
  16. Stark D, Barratt JLN, van Hal S, Marriott D, Harkness J, Ellis JT. Clinical significance of enteric protozoa in the immunosuppressed human population. *Clin Microbiol Rev.* 2009;22:634–50.
  17. Thellier M, Biligui S, Desportes-Livage I, Accoceberry I, Detry A. Monoclonal antibody enabling the diagnosis of *Encephalitozoon intestinalis* in fecal specimens: importance of the mode of selection of hybridomas. *J Eukaryot Microbiol.* 2001;Suppl.:71S–2S.
  18. Tosoni A, Nebuloni M, Ferri A, Bonetto S, Antinori S, Scaglia M, et al. Disseminated microsporidiosis caused by *Encephalitozoon cuniculi* III (dog type) in an Italian AIDS patient: a retrospective study. *Mod Pathol.* 2002;15:577–83.
  19. Weber R, Bryan RT, Schwartz DA, Owen RL. Human microsporidial infections. *Clin Microbiol Rev.* 1994;7:426–61.
  20. Weiss LM. Microsporidia: emerging pathogenic protists. *Acta Trop.* 2001;78:89–102.